

Voxel-wise assessment of WM architecture integrity in MS patients with different clinical phenotypes

E. Pagani¹, M. A. Rocca^{1,2}, G. Riccitelli¹, V. Martinelli², F. Martinelli-Boneschi², A. Falini³, G. Comi², and M. Filippi^{1,2}

¹Neuroimaging Research Unit, Institute of Experimental Neurology, Division of Neuroscience, Scientific Institute and University Hospital San Raffaele, Milan, Italy, ²Department of Neurology, Scientific Institute and University Hospital San Raffaele, Milan, Italy, ³Department of Neuroradiology, Scientific Institute and University Hospital San Raffaele, Milan, Italy

Introduction. Diffusion tensor (DT) magnetic resonance imaging (MRI) is sensitive to microstructural damage in multiple sclerosis (MS).

Objective. In this study, we used tract-based spatial statistics (TBSS) to compare white matter (WM) integrity abnormalities among MS patients with the major disease clinical phenotypes.

Methods. Using a 3.0 Tesla scanner, brain T2, T1 and DT MRI scans were acquired from 199 MS patients (34 benign [B] MS, 81 relapsing-remitting [RR] MS, 50 secondary progressive [SP] MS, and 34 primary progressive [PP] MS) and 89 sex- and age-matched healthy controls (HC). TBSS (<http://www.fmrib.ox.ac.uk/fsl/tbss/index.html>) was applied for voxel-wise analysis of fractional anisotropy (FA) and mean diffusivity (MD) maps. Significant differences were reported at a threshold of 0.05, family-wise error corrected.

Results. Compared to HC, RRMS patients had a significant FA decrease in the majority of the skeleton voxels. Similar results were found in PPMS, who, however, had a sparing of the cerebellum, cingulum and splenium and genu of the corpus callosum (CC). Compared to RRMS, SPMS patients showed a generalised decrease of FA. FA was decreased in the majority of WM tract in BMS vs. RRMS, except for the cerebellum (Figure 1). Compared to HC, RRMS patients had significant MD increase in the majority of skeleton voxels, with a sparing of the cerebellum; PPMS had an overlap between areas of increased MD and those of decreased FA. Compared to RRMS, SPMS patients had an increase MD in the CC, fornix and the anterior portion of the cingulum. No difference was found between RRMS and BMS, whereas compared to BMS, SPMS had a diffuse increase of MD in the infratentorial regions and in the anterior portion of the CC (Figure 2).

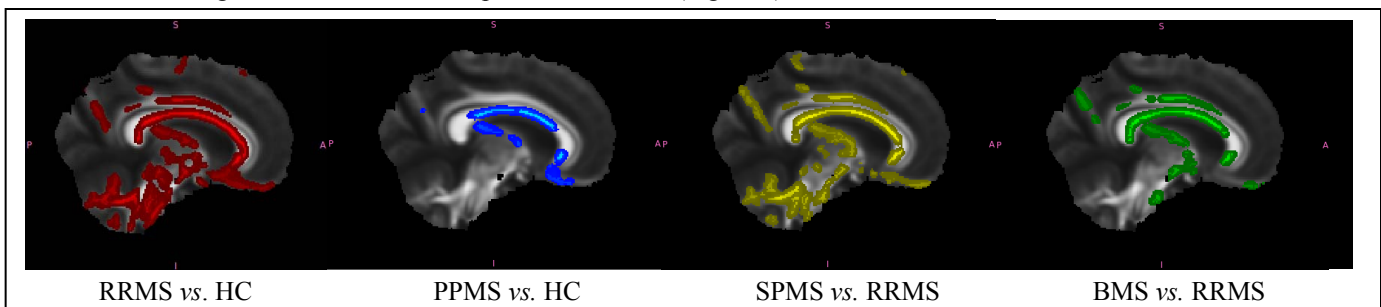


Figure 1. Fractional anisotropy differences.

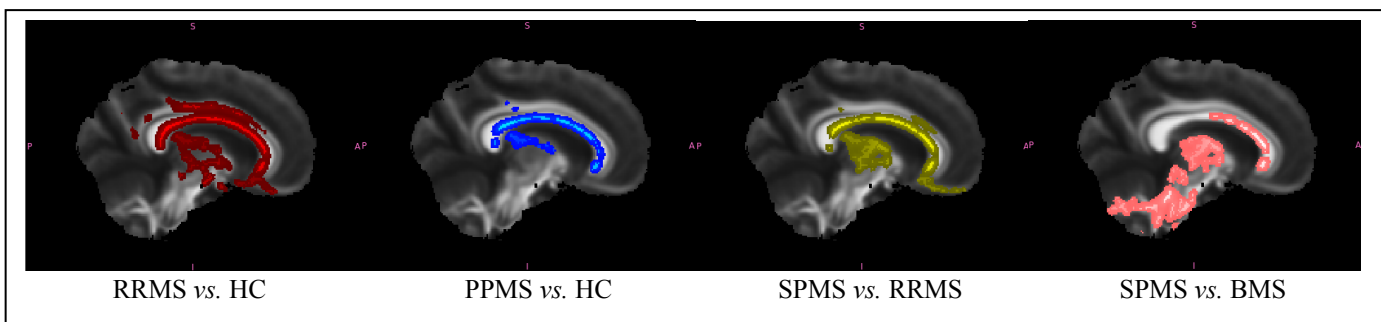


Figure 2. Mean diffusivity differences.

Conclusion. Diffuse WM microstructural abnormalities occur in all MS patients, but with a different topographical pattern in the different clinical phenotypes. Interestingly, while the supratentorial regions of the brain showed changes of both FA and MD in all the disease phenotypes, the involvement of the infratentorial regions differed markedly among the various clinical phenotypes (spared in PPMS, heterogeneously damaged in RRMS and SPMS, less damaged in BMS vs. SPMS). This suggests that the assessment of damage in these regions might contribute to a better characterization of the MS phenotypes.

Acknowledgments. The study was partially supported by a grant from FISM/2008/R/13.