

Comparison of the uptake of Gadolinium contrast agents between pre-clinical colorectal and other tumour models by dynamic contrast enhanced magnetic resonance imaging.

I. Wilson¹, G. S. Almeida¹, H. D. Thomas², D. R. Newell², and R. J. Maxwell¹

¹Newcastle MR Centre, Newcastle University, Newcastle Upon Tyne, Tyne and Wear, United Kingdom, ²Northern Institute of cancer Research, Newcastle University, Newcastle Upon Tyne, Tyne and wear, United Kingdom

Background Our focus is on the development of MR and PET imaging agents for the evaluation of novel cancer treatments. Tumour vasculature is an important determinant of key features of the micro-environment such as hypoxia, pH and the delivery of both drugs and molecular imaging agents. In addition, there is wide interest in anti-vascular and anti-angiogenic drugs since they could have a selective effect in destroying or inhibiting the formation of tumour vessels, therefore depriving tumour cells of nutrients and contributing to tumour cell death. Dynamic contrast enhanced MRI has been used in various phase I clinical trials to evaluate the extent and time course of anti vascular drugs such as combrestatin-A4-phosphate. As part of our development of new lanthanide contrast agents and in order to characterise tumour models for use with PET imaging studies, we have compared two standard gadolinium based contrast agents in a range of animal tumour models.

Aims The aim of this study was to evaluate the uptake of two similar gadolinium contrast agents Gadoteridol (Prohance) and Gadobutrol (Gadovist) in various pre-clinical human tumour xenograph models using dynamic contrast enhanced magnetic resonance imaging.

Methods Mice were implanted subcutaneously with various human tumour xenographs (HT29 colorectal, SW620 colorectal, HCT116 colorectal, HUH7 hepatoma, A2780 ovarian and SJSA1 osteosarcoma). When the tumours reached 10mm in diameter they were prepared for MRI as follows. Animals were anaesthetised with a mixture of oxygen and 1-2% Isoflurane and their lateral tail veins cannulated, mice were then restrained inside a 39 mm 1H birdcage coil (Rapid) and respiration and temperature monitored. Animals were kept warm by a feedback enhanced hot air system (SA instruments). Imaging took place in a 7 Tesla horizontal bore magnet of a Varian MR spectroscopy/imaging system. A sequence of 100 gradient echo images were obtained every 6 seconds for 10 minutes; 5 images before administration of contrast agent followed by infusion of a dose of 0.1mMol Kg⁻¹ Gadoteridol (Prohance, Bracco Imaging) or Gadobutrol (Gadovist, Schering), in a volume of 200 µl given over 6 seconds. The MRI parameters used were: TR 23.45 ms; TE 4.40 ms; 2mm slice thickness and a field of view of 40 x 40 mm with 256 x 256 data points. Images were analysed for intensity increases over time in whole tumour regions of interest using Image J software (NIH image).

Results Tumour uptake of gadovist varied over the tumour types with HCT 116 showing the least uptake (15%) and SJSA1 showing the greatest (41%), although the intensity is the same in A2780 and HUH7 levels after 10 minutes (figure 1). Overall Gadovist seems to give a greater intensity increase over Prohance although this is not significant (figure 2). The colorectal tumours take up significantly less contrast agent compared to the 3 others studied. (P = 0.018 colorectal vs others with Prohance, N = 9 and P = 0.02 colorectal vs others with Gadovist, N = 9).

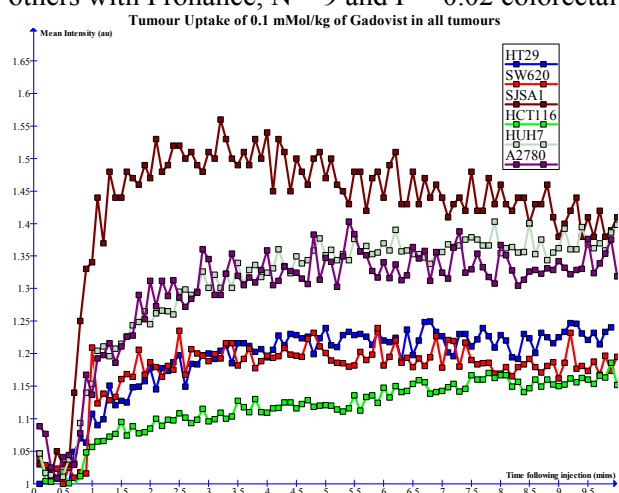


Figure 1. Tumour uptake of Gadovist. Showing increases in intensity over time for all 6 tumour types. N=3.

Conclusions Colorectal pre-clinical tumour models show significantly different degrees of Gadolinium contrast agent uptake to our other tumour models studied. These provisional DCE MRI experiments helped us to identify model-specific tumour uptake patterns that we used for further development of MR contrast agents and PET tracers.

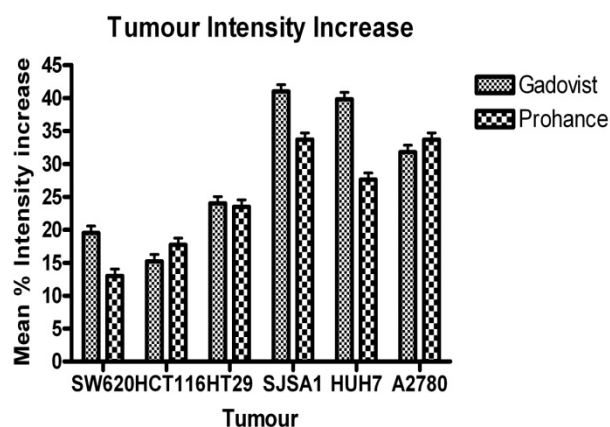


Figure 2. Percentage increase in intensity for both Gadovist and ProHance. N = 3, +/- SEM.