

Measurements of RF Heating During 3.0T MRI of a Pig Implanted with DBS

K. R. Gorny¹, S. J. Goerss², M. F. Presti³, S. Hwang⁴, D-P. Jang⁴, I. Kim⁴, K. H. Lee⁵, and M. A. Bernstein¹

¹Radiology, Mayo Clinic, Rochester, MN, United States, ²Neurosurgery, Mayo Clinic, Rochester, MN, United States, ³Neurology, Mayo Clinic, Rochester, MN, United States, ⁴Neurologic Surgery, Mayo Clinic, Rochester, MN, United States, ⁵Neurologic Surgery, Mayo Clinic, Rochester, MN

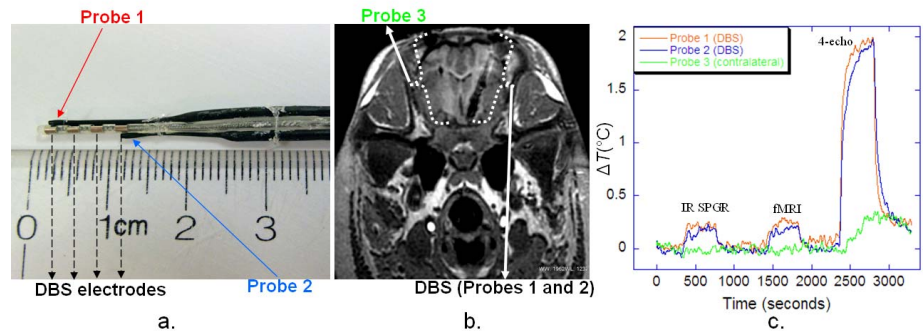
Introduction

Deep brain stimulation (DBS) therapy is used to treat a range of neurological conditions. High-frequency electric pulses stimulate the subthalamic nucleus (STN) or other areas within the brain. The DBS system is surgically implanted with the implantable pulse generator (IPG) in the chest and DBS lead(s) in the brain. MRI brain examinations of DBS patients at 1.5T are considered safe provided a transmit-receive (TR) coil is used, average head specific absorption rate (SAR) is limited to 0.1 W/kg, and the IPG output is switched off. Currently, the manufacturer's guideline advises against 3.0T MRI scanning [1]. 3.0T MRI is widely used, and considered the field strength of choice for clinical high-resolution brain MRI, fMRI, diffusion tensor, and ASL. For these reasons, 3.0T MRI examinations in DBS patients have been the subject of ongoing clinical [2] and phantom studies [3]. These examinations, however, could pose a serious safety concern especially due to potential for harmful RF heating of conducting DBS electrodes and surrounding tissue. This work aims to directly measure local temperature changes near the DBS electrodes during 3.0T MRI scanning in a pig model.

Methods

Two fluoroptic thermometers (Luxtron, model 750) were attached directly to DBS electrodes (Medtronic, model 3389) as shown in Figure 1a. The DBS was then surgically implanted in the STN of anesthetized 31 kg pig under an IACUC-approved protocol. Third probe was placed contralaterally within the STN, approximately 10mm from the DBS lead tip (Figure 1b). The fourth probe was attached to the surface of Soletra IPG (Medtronic, model 7426), which was implanted in the prone pig's back to simulate a supine human's chest placement. The 3.0T and 1.5T scanning (GE Healthcare, 14.0software) was performed with the pig's head placed in a Leksell stereotactic frame inside the TR head coil. Three different 7 minute pulse sequences were played per each measurement (run): 4-echo spin echo (ASTM heating standard), IR-FSPGR, and resting-state fMRI (GRE EPI). A cooling interval of 5 minutes was applied between each sequence. At 3.0T, five repeated runs were performed: with IPG off (2 runs) and IPG on (3 runs), and with the pig's head shifted 2cm along z-axis (1 run) and tilted by 3° (1 run). An additional run, at 1.5T, was also performed as a reference standard. The IPG operational status was verified after each run. The following values were recorded: displayed average coil SAR, power monitor plateau value of the 6-minute SAR average (3.0T only), and auto prescan transmit gain (TG) corresponding to each sequence. The animal studies were supplemented with measurements of TG as a function of patient weight on 15 volunteers under an IRB-approved protocol. The volunteer data were fit with a linear-least squares method, and then with the methods described in [4] used to obtain human-equivalent SAR_C values corresponding to SAR_D displayed based on 31 kg weight entered for the pig.

Figure 1: a. Attachment of fluoroptic probes to DBS electrodes (with superglue and tethers). b. Axial image of pig's head showing DBS lead and contralateral fluoroptic probe (white arrows). c. Example temperature elevations measured during executions of the three RF pulse sequences.



Results

Maximal temperature increases, ΔT_{Max} , measured on DBS electrodes during 3.0T and 1.5T MRI scanning are shown in the Table. The 3.0T data (mean and standard deviation) are based on all five measurements. SAR_D displayed average coil SAR, SAR_C "corrected" average coil SAR, SAR_{PM} power monitor 6 min. average (3.0T only). Heating at the contralateral probe can be accounted for by the deposition of RF energy. No heating was observed at the IPG.

Conclusions

Limitations of the study include differences in pig versus human anatomy, and sensitivity of the temperature rise to the details of lead placement. Much caution should be exercised when extrapolating these results. Nevertheless it is encouraging that 3.0T MRI using low SAR fMRI and IR-FSPGR sequences resulted in local temperature elevations at DBS electrodes of no more than 0.3°C. These data, in conjunction with further phantom studies, could be used to address safety concerns of 3.0T MRI in patients with implanted DBS devices.

[1] Medtronic, Inc 2006 http://professional.medtronic.com/wcm/groups/mdtcom_sg/@mdt/@neuro/documents/documents/dbs-2007-mri.pdf; [2] Phillips MD *et al. Radiology* **239** (2009): 209-216; [3] Carmichael DW *et al. Neuroimage* **37** (2007): 508-517; [4] Gorny KR *et al. Phys Med Biol* **53** (2008): 2565-2576

Pulse Sequence	3.0T				1.5T		
	SAR _D (W/kg)	SAR _C (W/kg)	SAR _{PM} (W/kg)	ΔT_{Max} (°C)	SAR _D (W/kg)	SAR _C (W/kg)	ΔT_{Max} (°C)
4-echo	2.20	2.70	3.1	1.83 ± 0.28	0.67	1.04	2.61
fMRI	0.32	0.41	0.4	0.27 ± 0.08	0.02	0.03	0.17
IR-FSPGR	0.35	0.49	0.5	0.28 ± 0.08	0.09	0.14	0.37