

Pain control in patients with locally advanced pancreatic carcinoma using High Intensity Focused Ultrasound under 3T MR Guidance. Results from a single center preliminary experience.

A. Napoli¹, B. Cavallo Marincola¹, M. Anzidei¹, G. Menichini¹, G. Cartocci¹, C. Catalano¹, and R. Passariello¹

¹Radiological Sciences, Policlinico Umberto I, Rome, Italy

PURPOSE

To evaluate the efficacy of non-invasive high intensity MR guided focused Ultrasound (MRgFUS) treatment for pain palliation in patients with pancreatic adenocarcinoma not indicated for surgical resection.

METHOD AND MATERIALS

Upon local IRB approval, three patients with biopsy-proven pancreatic adenocarcinoma (respectively 59, 64 and 62 years old) underwent high intensity MRgFUS treatment for local pain control. MRgFUS treatment was performed beyond standard chemiotherapeutic drugs using the ExAblate 2000 system (InSightec). Lesions were localized at pancreatic isthmus (n=2) and body (n=1). Effectiveness of pain palliation was evaluated at baseline and follow-up using the visual analog pain score (VAS) and measurable changes in analgesics intake. Patients underwent CT and MR examinations before, immediately after and 3 months after the treatment. For tumor control perfusion T1weighted images were obtained pre- and post-treatment in order to determine the non-perfused sonication-related area.

RESULTS

All pancreatic lesions were treated. At baseline median value of VAS was 7.6; it was 6.6 after one week and 5.6 after 3 months. No heating related adverse event were recorded during this clinical application; patient medication intake was considerably reduced in two patients. One patient, in whom recurrent pain was observed at follow-up, celiac trunk alcoholization was required.

CONCLUSION

MRgFUS is a promising non-invasive treatment modality for successful palliation and control of pain in patients with pancreatic neoplasms. Further studies are need in order to obtain a greater control of both local tumor and surrounding tissues invasion.

CLINICAL RELEVANCE/APPLICATIONS

MRgFUS can represent a viable choice for the pain control in patients with pancreatic adenocarcinoma.

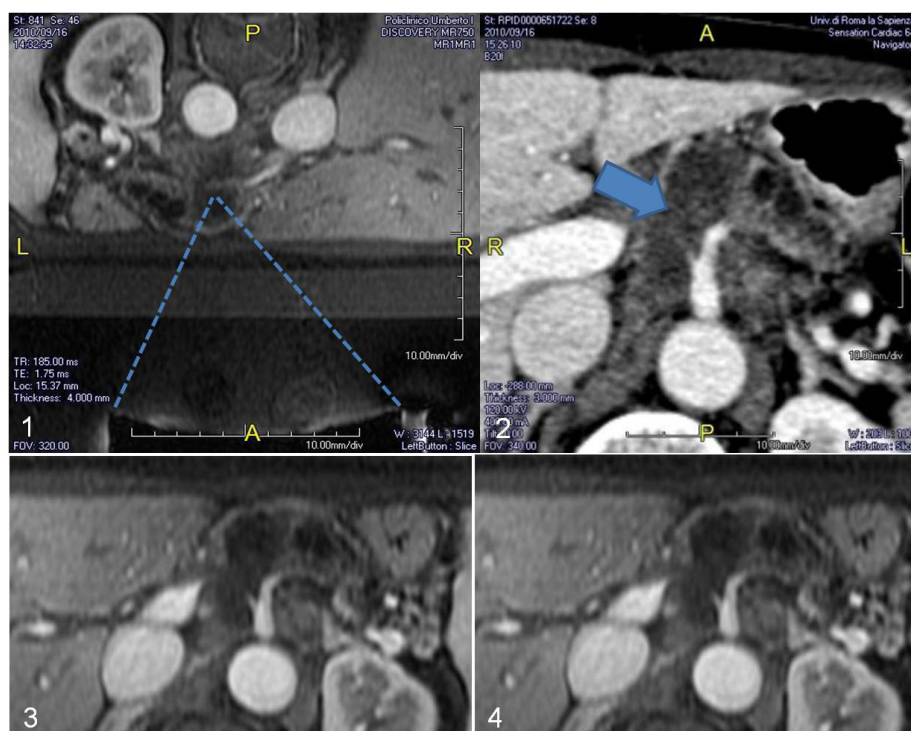


Figure:1) Woman with abdominal pain due to the presence of an infiltrating pancreatic tumor; schematic localization of the FUS beam path from the transducer to the pancreatic neck. 2) After the treatment the axial CE CT-image shows presence of necrosis around the celiac trunk due to sonications. Similarly, CE MR images (bottom line 3-4) acquired at two weeks demonstrate large necrotic area induced by non-invasive, well tolerated MRgFUS treatment; area of necrosis reached the celiac trunk sparing it; no vascular damage was observed at both immediate and subsequent follow-up. Patient experienced immediate pain relief and analgesic intake was discontinued. Due to overall local invasion progression, patient reintroduced analgesics 1 month later.