

Imaginary toe-tapping causes classic motor hand area activation in bilateral upper limb amputees

F. Zhao^{1,2}, H-J. He³, X-J. Yu², Y-X. Wang¹, and S-Z. Zhang²

¹Department of Imaging and Interventional Radiology, The Chinese University of Hong Kong, Shatin, N.T., Hong Kong, China, People's Republic of, ²Department of Radiology, Sir Run Run Shaw Hospital, Hang Zhou, Zhe Jiang, China, People's Republic of, ³Bio-X laboratory of Physics Department, Zhejiang University, Hang Zhou, Zhe Jiang, China, People's Republic of

Introduction: Previous researches suggested an expansion of the adjacent cortical representations into the cortical area representing the deafferented body part after amputation [1]. This suggests the cortical area representing the missing hand involved the motor control of the lip and the stump following the amputation of upper-limb. It was reported that the cortical hand area activation is elicited during toe-tapping in bilateral upper-extremities amputees with extraordinary foot movement skill [2]. To our knowledge, cortical activation during imagined toe tapping in bilateral upper limb amputees has not previously been investigated. In this study, we used fMRI to investigate the cortical activation in three bilateral upper limb amputees when they executed real and imagined toe-tapping.

Materials and methods: Subjects: With informed consent, three bilateral upper limb amputees and seven age-matched control subjects participated in the study. According to foot movement skill performance test [2], Amputee case 1 and Amputee case 2 have extraordinary foot movement skills, they both manage their daily living activities with their feet dexterously, even threading and needling. Amputee case 3 and the control subjects have no special foot movement skills. All amputees' right feet are dominant, and they were right-handed before amputation. All control subjects are right-handed. **fMRI study design and procedure:** Participants were asked to perform two tasks: 1) real movements of the right toes (real toe-tapping), and 2) imagery movements of the right toes (imaginary toe-tapping). Participants rehearsed the task outside the scanner immediately before the scanning session, including having the opportunity to practice while listening to an MP3 of the noise of the EPI scans. Participants accepted commands acoustically, which was edited by the digital voice editor of Goldwave 5.12. The frequency of execution and imagined movement of toe-tapping was controlled by the voice rhythm, which was at a rate of 0.5 Hz. The scanning paradigm consisted of a simple block design. After 30 s of rest, the task (actual right toe-tapping or imaginary right toe-tapping) was performed for 30 s, followed by another 30 s of rest, for a period of 6 min. All participants were instructed to close their eyes during the fMRI scan and not to think of another thing during the task conditions. Two investigators stayed in the scanning room with each subject for visual monitoring during scanning to ensure accuracy of performance without extraneous movement. **MRI measurement:** The subjects were lying supine with their eyes closed in the scanner with the head and the proximal limb securely fixed to minimize involuntary movement. All scanning was performed on a 1.5-T MR scanner (GE1.5T Signa CV/I) equipped with echo-planar imaging (EPI) capability. Firstly, the T1-weighted spin echo sequence (TR=500 ms, TE=16 ms, slice thickness=5 mm, gap=1 mm, matrix=256*256, FOV=24*24 cm) scanned anatomical images. Slices were parallel to the anterior commissure-posterior commissure line, 26 sections. Secondly, Functional images were acquired with an EPI sequence (TR=2000 ms, TE=50 ms, FOV=24*24 cm, slice thickness=5 mm, gap=1 mm, matrix=64*64, NEX=1) using an axial slice orientation same as the first step. Lastly, a 3D T1-weighted spoiled gradient recall echo sequence (thickness = 1 mm, matrix=256*256, FOV=24*24 cm, sagittal plane) was used to collect a whole 3D brain volume. **Image analysis:** Image analysis was performed using SPM2 software (Wellcome Department of Cognitive Neurology, London, UK; <http://www.fil.ion.ucl.ac.uk/spm/software/spm2>) implemented in MATLAB (MathWorks, Natick, MA). The first eight functional images (corresponding to the dummy run) were discarded to allow for T1 equilibrium effects; the remaining images were realigned to each other to correct for interscan movement artefacts. The echo planner images of each subject were coregistered to the anatomical data sets after the anterior commissure had been defined manually as the reference point. The echoplanner imaging data were smoothed with a Gaussian filter of 6-mm full-width at half-maximum (FWHM). Differences in activation intensity between the subjects were evaluated with the t-tests ($p < 0.05$) and displayed as statistical parametric maps, those within clusters of > 5 voxels were reported from selected areas. We focused on whether the activation of classic motor hand area was found in the amputees during imagery toe-tapping task.

Results: The rate and amplitude of toe movements during the execution of toe-tapping task showed little intraindividual and interindividual variations, as judged independently by two investigators. None of the subjects displayed overt toe motion during the imagery conditions. We focused on the PMC (primary motor cortex), the M1 foot area [3] activation was found in control subjects during executing real toe-tapping as well as imagined toe-tapping. Interestingly, the real toe-tapping of amputees activated contralateral M1 foot area and classic hand area ("Ω" area or "ε" [4]). The imaginary toe-tapping activated contralateral foot zones and classic hand area as well. The cortical activation maps were showed in Fig. 1.

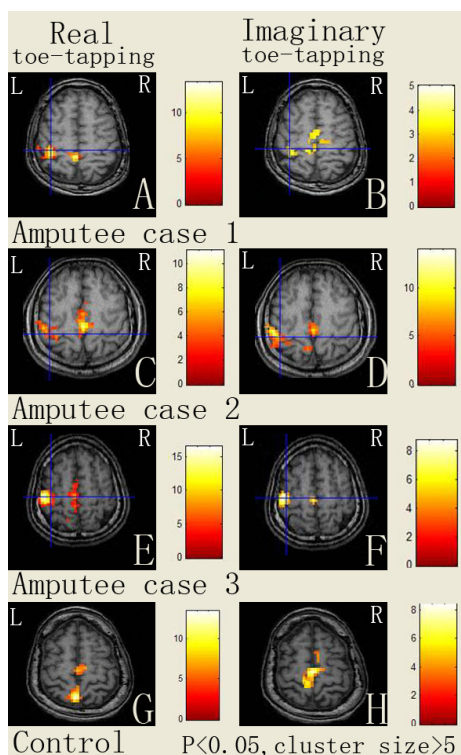


Fig. 1. The cortical activation during executing task of real toe-tapping and imagined toe-tapping in amputees (amputee case 1: A&B; amputee case 2: C&D; amputee case 3: E&F) and control (G&H). Amputees (amputee case 1, 2 and 3) demonstrated activation not only in contralateral M1 foot area, but also in classic hand area ("Ω" area or "ε" [4]) during real and imaginary toe-tapping of right toe. The mapping of control subjects (G&H) showed that when executed and imagined toe-tapping of right toe, the foot zones [3] of the contralateral primary motor cortex are active.

Discussion: This study showed that the cortical area representing the missing hand was activated by executed as well as imagined toe tapping in amputees with or without extraordinary foot movement skill, which wasn't found in normal subjects. Our data suggest that after amputation the cortical reorganization is not limited to the adjacent cortex and the area representing the missing hand also controls the real foot movement as well as the imagined foot movement.

References: [1] Irlbacher K, Meyer BU, Voss M, et al. Spatial reorganization of cortical motor output maps of stump muscles in human upper-limb amputees. *Neurosci Lett* 2002; 321: 129-32. [2] Yu X, Zhang S, Liu H, et al. The activation of the cortical hand area by toe tapping in two bilateral upper-extremities amputees with extraordinary foot movement skill. *Magn Reson Imaging*. 2006 24(1):45-50. [3] Ehrsson HH, Geyer S, Naito E. Imagery of voluntary movement of fingers, toes, and tongue activates corresponding body-part-specific motor representations. *J Neurophysiol*. 2003 90(5):3304-16. [4] Yousry TA, Schmid UD, Alkadhi H, et al. Localization of the motor hand area to a knob on the precentral gyrus. A new landmark. *Brain*. 1997 Jan; 120 (Pt 1):141-57.