

## Rodent Glioma Chemotherapy and Sodium MRI at 21.1T

V. D. Schepkin<sup>1</sup>, F. Calixto Bejarano<sup>1</sup>, T. Morgan<sup>2</sup>, S. Gower-Winter<sup>2</sup>, and C. W. Levenson<sup>2</sup>

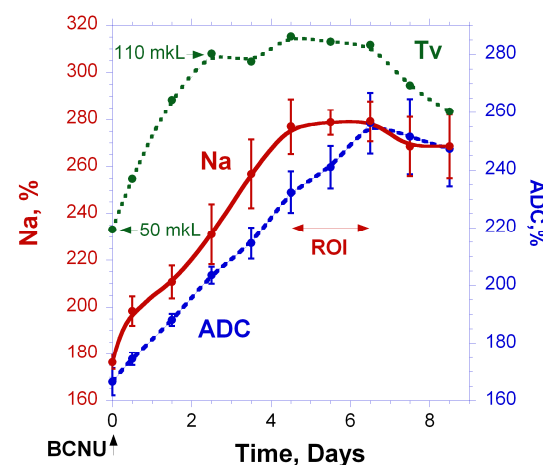
<sup>1</sup>CIMAR/MRI, NHMFL/FSU, Tallahassee, Florida, United States, <sup>2</sup>Biomedical Sciences, FSU, Tallahassee, Florida, United States

### Introduction

The diagnostic value of sodium MRI has not been established. Consequently, its biomedical role is under thorough investigation. The current project was inspired by multiple experiments, demonstrating that increased intracellular sodium *in vitro* is either capable to initiate or to be an indicator of apoptosis (1-9). The hypothesis tested here was that the increase of intracellular sodium during apoptosis occurs not only *in vitro* but *in vivo* as well. The advanced approach was implemented in the present experiments to perform this task. It included MRI at the ultra high magnetic field of 21.1T, a double tuned Na/H RF probe to minimize the interval between Na/ADC scans, and an ultra-short echo time back projection imaging to detect the total sodium signal. All was combined with the highest resolution to avoid partial volume effects. And, finally, motion compensation was applied during post-processing. The importance of this project is supported by the growing evidence that a disruption of sodium homeostasis can serve as an important primary or secondary tool in our fight against cancer (2,7-9,10).

### Materials and Methods

Five male Fisher 344 rats (weight ~ 150 g) were implanted intra-cranially with 9L gliosarcoma cells. Later, in 10 days, a single dose IP carmustin (BCNU, 26.6 mg/kg) was injected. Tumor sodium, diffusion and volume were evaluated daily, over a 10 day course. The MRI experiments were conducted at the 21.1T MRI scanner using a double tuned RF probe (proton/sodium frequency = 900/237 MHz), Bruker Avance III console and RR Inc. gradient coil (ID=64mm). Sodium 3D back-projection MRI scans had a resolution of 0.5x0.5x0.5 mm and a duration of 27 min. FID detection delay was ~0.1 ms and TR=100 ms. The diffusion SE pulse sequence had flow/motion compensated 3D diffusion gradients with two "b" values of 100 and 1000 (sec/mm<sup>2</sup>), TE=34 ms, 15 slices, thk = 0.7 mm and provided images with resolution 0.1x0.1 mm. Back projection MRI mode for sodium and ADC offered additional opportunities for motion compensation. Both sodium and diffusion MRI were performed on the same animal without its repositioning. Na/ADC measurements are presented in percent relative to a normal contra-lateral part of the brain, where ADC is ~0.78\*10<sup>-3</sup> mm<sup>2</sup>/sec and sodium content ~ 50 mM. Tumor volumes were determined as a sum from all diffusion slices detecting tumors. All experiments were conducted according to the animal protocols approved by The Florida State University ACUC.



### Results and Discussion

All five time courses of sodium, diffusion and volume in tumor have the same pattern. A typical one is presented in Fig. 1 demonstrating accuracy of experiments for a single animal. The sodium in the tumor aggressively increases immediately after BCNU injection and reaches its maximum in 4.5 days at the level of ~ 280% (140 mM). However, diffusion still continues to reflect the changes in tumor cellularity as can be observed from the ongoing increase of ADC values. Lack of change in sodium while diffusion is increasing indicates that tumor cells lost their sodium gradient at this time. On average sodium reached its maximum in 4.7±0.8 days, while the highest levels in ADC were achieved around 7±0.6 days, thus the high sodium levels in tumor remain unchanged for ~2.3 days. It is interesting to note that attaining this high level of sodium is necessary before tumors start to shrink. Tumor size reductions of 30%, required to define a partial response, were observed in ~9 days, while the initial stages of the positive tumor response can be reliably detected by both sodium and diffusion in one day.

**Fig. 1.** Typical time course of sodium, diffusion and volume in a rodent glioma after a single dose of BCNU injection (26.6 g/Kg), error bars represent stdev.

### Conclusion

Initial therapeutic sodium responses in glioma were evaluated and compared with corresponding changes in tumor ADC. The time courses of tumor reactions reveal a loss of tumor sodium intracellular gradient early during therapy, thus demonstrating the fact that it can be a part of the *in vivo* apoptotic process. The results also represent the differences between sodium and diffusion MRI. An especially noteworthy feature is that sodium is responding earlier than diffusion. The effect of positive therapy can be evaluated for each animal individually in a day after initiation of treatment. Sodium and ADC are valuable MRI biomarkers and can serve as efficient tools for drug development.

### Acknowledgements

Special thanks to P. Gor'kov, C. Qian, W. Brey, R. Desilets for the double tuned probe development, A. Blue and M. Ozambela, Jr. for their valuable support during this project. The study was supported by NIH Grant R21 CA119177. The MRI imaging program at NHMFL is supported by NSF Cooperative Agreement (DMR-0654118), the State of Florida and US Department of Energy.

**References** (1) Lefranc, F. et al. *Neoplasia* 2008, 10(3): p198. (2) Chen J.Q. et al. *Breast cancer research and treatment*, 2006, 96:p1. (3) Sontheimer, H. J. *Neurochem.* 2008, 105: p287. (4) Arrebola, F. et al. *J Cell Physiol* 2005, 204: p500. (5) Svensson A. et al. *Anticancer Res* 2005, 25: p207. (6) Mijatovic T. et al. *Biochim Biophys Acta* 2007, 1776: p32. (7) Prassas I. et al. *Nature Reviews* 2008, 7:p926. (8) Bortner, C.D. et al. *Arch Biochem Biophys* 2007, 462:p176. (9) Newman, R.A. et al. *Mol Interv* 2008, 8:p36. (10) Panayiotidis, M.I. et al. *Apoptosis* 2010, 15:p834.