

Normal distribution on blood flow helicity in the healthy aorta

R. Lorenz¹, J. Bock¹, J. G. Korvink^{2,3}, and M. Markl¹

¹Dept. of Radiology, Medical Physics, University Medical Center Freiburg, Freiburg, Germany, ²Dept. of Microsystems Engineering - IMTEK, University of Freiburg, Freiburg, Germany, ³Freiburg Institute of Advanced Studies (FRIAS), University Freiburg, Freiburg, Germany

Introduction: 3D blood flow characteristics in the aorta play an important part in the health of individuals. However, *in vivo* blood flow patterns are complex and dependent on the individual geometry and shape of the aorta. Previous studies have shown that normal aortic hemodynamics include specific flow patterns that deviate from the physiological flow direction. Helix flow, an overall corkscrew-like motion of blood along the direction of flow, is considered a normal feature in aortic blood flow. To date, however, the variation in existence and extent of helical flow in the healthy aorta has not been investigated in detail. Most recent studies have analyzed helical flow characteristics visually [1] or using a global helical flow index [2]. The aim of this study was to implement a quantitative analysis strategy to evaluate the spatial distribution and temporal dynamics of helix flow in the entire thoracic aorta. Analysis was based on helicity quantification in 2D analysis planes distributed along the aorta for 12 healthy subjects.

Methods: After ethical approval and written informed consent 12 healthy subjects (n=12, mean age=23±3) were examined on a 3T system (MAGNETOM Trio Tim, Siemens, Germany). ECG synchronized prospectively gated and respiration controlled navigator gated flow-sensitive MRI with 3-dir. velocity encoding was performed using a sagittal oblique 3D volume to cover the entire aorta. Scan parameters were as follows: TE/TR = 2.6/5.1ms, flip angle = 7°, temporal resolution = 40.8ms, spatial resolution = 1.7x2.0x2.2mm³. Flow-sensitive 4D MR images were corrected for eddy currents, Maxwell terms and velocity aliasing. The time-averaged magnitude (sum of squares) of the absolute velocities was used to calculate phase-contrast angiography (PC-MRA) data. PC-MRA was used for anatomic orientation in 3D (EnSight, CEI, USA) and to position equally spaced (distance = 10mm) analysis planes along the entire thoracic aorta. The first analysis plane was positioned directly distal to third supra-aortic branch (see figure 1 (p0)) to define a common geometric landmark. The analysis planes covered the ascending aorta, the aortic arch, and the proximal descending aorta. For each analysis plane, the aortic lumen for all time-frames was manually segmented (Matlab, The Mathworks, USA) and mean helicity and peak mean helicity was determined. For each pixel in the segmented lumen, normalized helicity was calculated as helicity

$$= \cos(\alpha) = \frac{\vec{v} \cdot \vec{w}}{|\vec{v}| |\vec{w}|}$$

where \vec{v} is the velocity vector and \vec{w} the vorticity vector resulting in values

between -1 (counter clockwise rotation) and +1 (clockwise rotation) [3]. For each analysis plane, helicity was average over the segmented aortic lumen. The temporal evolution of mean helicity over the cardiac cycle was thus derived for all analysis planes and volunteers.

Results: Helicity was evaluated in a total number of 254 analysis planes (average per volunteer = 21.2±1.8) distributed along the aorta. Figure 1 depicts time resolved mean helicity averaged over all 12 subjects for five selected analysis planes. The top graph in figure 1 shows the temporal evolution of helicity averaged for all planes in the ascending aorta (AAo, gray), the aortic arch (AA, green) and the descending aorta (DAo, blue). In the ascending aorta, positive mean helicity during systole indicated clockwise rotation (red arrow), which changed to counter clockwise rotation during early diastole (blue arrow). Further along the ascending aorta peak systolic helicity increased and was further delayed while diastolic (negative) helicity decreased in magnitude. The aortic arch showed only high clockwise rotation during systole but no diastolic helix flow. Further downstream in the descending aorta, diastolic helix flow reappeared, however with opposite sense of rotation compared to the ascending aorta: systolic counter clockwise helix flow and diastolic clockwise helicity. The systolic peak helicity and the end systolic/early diastolic peak helicity for all subjects are illustrated as boxplots in figure 2. The change in flow rotation directions in AAo and arch compared to the DAo can clearly be appreciated (sign changes of peak helicity). The ranges of the box plots provide an impression of the inter-individual variability of peak systolic and diastolic helix flow and indicate a consistent helix orientation and magnitude between individuals. Figure 3 shows interpolated time-averaged helicity between all planes along the aorta for each subject. For all subjects, clockwise helical flow within the aortic arch with the highest mean helicity is clearly visible.

Discussion: In this study mean and peak mean helicity in 2D planes equally distributed along the aorta for 12 healthy subjects were analyzed. All 12 healthy subjects showed consistent directions of rotation over the entire aorta with high clockwise helicity and a good inter-individual agreement in the aortic arch. It is the first study providing a fully quantitative analysis and detailed evaluation of spatial and temporal distribution of helix flow and has the potential to serve as a reference distribution for comparisons to helix flow in patients. Future studies should investigate the influence of age and geometry of the aorta.

Acknowledgements: Grant support by the Deutsche Forschungsgemeinschaft, (DFG), Grant # MA 2383/5-1 and the Bundesministerium für Bildung und Forschung (BMBF), Grant # 01EV0706.

References: [1] Frydrychowicz et al., J. Comput. Assist. Tomogr., 2007, **31**(1), pp. 9-15, 2007, [2] Morbiducci et al., Annals of Biomed. Eng., 2009, **37**(3), pp. 516-531, [3] Moffatt et al., J. Fluid Mech, 1969, **35**, pp. 117-129

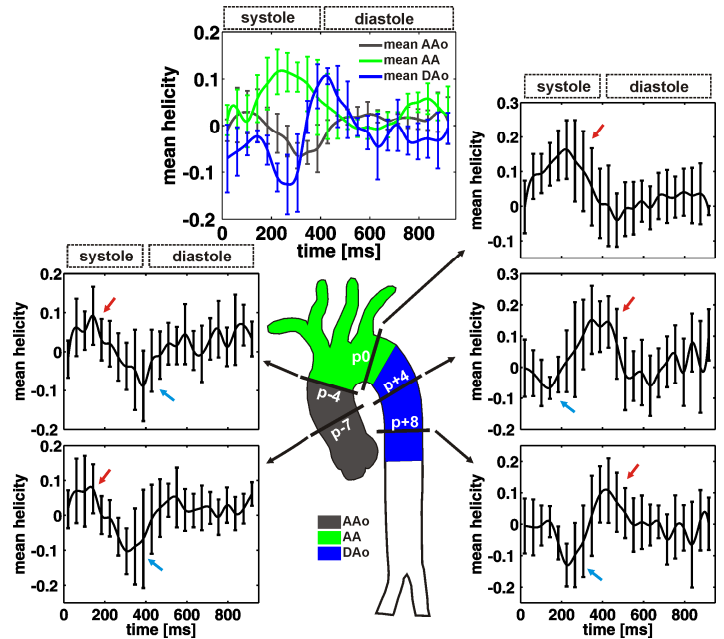


Fig. 1: Time resolved mean helicity averaged over all subjects for five planes along the aorta. The top plot shows averaged temporal helicity for the ascending aorta (AAo, gray), the aortic arch (AA, green) and the descending aorta (DAo, blue). Standard deviations reflect inter-individual variations.

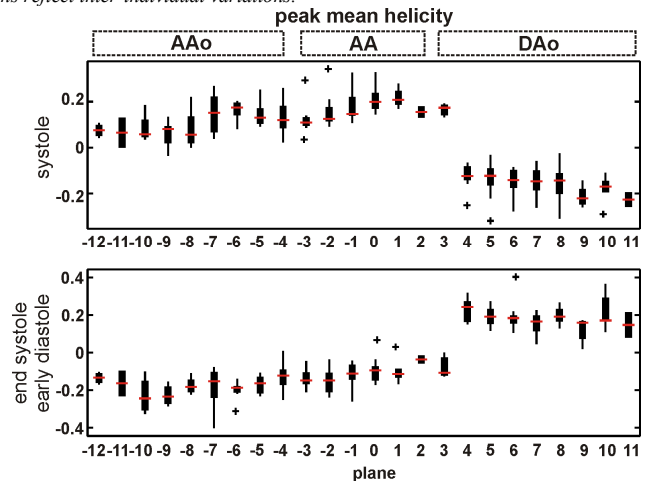


Fig. 2: Boxplots of peak mean helicity averaged over all 12 subjects showing the propagation of the first peak (top) and second peak (bottom) over all planes distributed along the aorta.

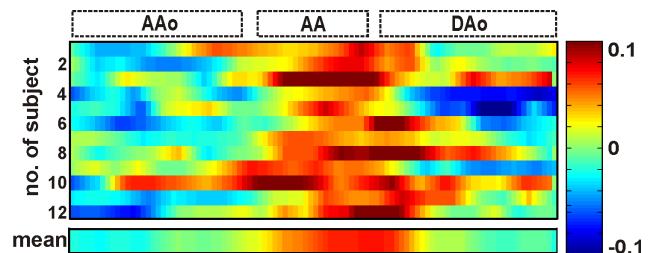


Fig. 3: Color coded and interpolated mean helicity over the entire aorta for all 12 healthy subjects and averaged over all subjects as indicated in mean. Clockwise rotation is indicated by red color, anti-clockwise rotation by blue color.