

## **Distribution of Cardiac Iron measured by MRI-R2\***

**J. Yamamura<sup>1</sup>, R. Grosse<sup>2</sup>, J. Graessner<sup>3</sup>, G. Janka<sup>2</sup>, G. Adam<sup>1</sup>, and R. Fischer<sup>4,5</sup>**

<sup>1</sup>Diagnostic and Interventional Radiology, University Medical Center Hamburg-Eppendorf, Hamburg, Germany, <sup>2</sup>Pediatric Hematology and Oncology, University Medical Center Hamburg-Eppendorf, Hamburg, Germany, <sup>3</sup>Siemens AG, Hamburg, Germany,

<sup>4</sup>Department of Biochemistry and Molecular Biology II: Molecular Cell Biology, University Medical Center Hamburg-Eppendorf, Hamburg, Germany, <sup>5</sup>Children's Hospital & Research Center Oakland, Oakland, California, United States

### **Abstract**

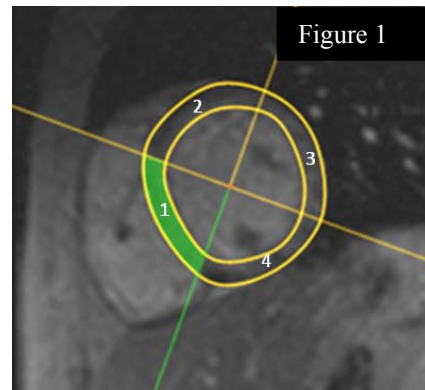
#### **Introduction**

Iron overload in the heart is the leading cause of death for thalassemia patients receiving chronic blood transfusions, since tissue damage in the myocardium leads to several complications, e.g. arrhythmias and congestive heart failure. Adequate chelation treatment minimizes iron accumulation, prevents organ damage, and thus decreases morbidity and mortality. The assessment of the cardiac iron concentration (CIC) has become an indispensable tool in the therapy management of thalassemia. The measurement of the septal R2\* (= 1/T2\*) in a mid-papillary short axis slice can be used for artifact-free cardiac iron measurements. The purpose of this study was to identify the variation of the transverse relaxation rate R2\* in a left ventricular mid-papillary cardiac slice and to find out the most appropriate site to measure the cardiac iron with the least artifacts and boundary effects.

#### **Material and Methods**

From this group, 32 patients (age: 7 – 79 y) with transfusional siderosis were selected in order to investigate the iron distribution in the myocardium. Breathhold prospective ECG gating was used on a 1.5 T (Tesla) imager (Symphony®, Siemens AG, Erlangen) with a four-element phased array coil. Localization of the heart along the 3 major orthogonal heart planes resulted in short axis, two and four chamber views. Saturation bands were used to minimize fold-over artifacts in the phase-encode direction. A cubic shim box restricted to the whole heart was applied. From a mid-papillary short axis slice of 10 mm thickness, the GRE (Gradient Recalled Echo) relaxation rate R2\* was analyzed from signal intensities of the cardiac septum and walls by mono-exponential fitting with constant signal level offset. For this measurement, a breathhold prospective ECG gated cardiac MRI sequence with data from 9 heartbeats in end-diastole with 12 echo times TE = 1.3 to 25.7 ms in end-diastole (Δt = 2.8 ms, TR = 243 ms, flip angle 20°, band width 1955 Hz/pixel, pixel spacing 1.25 mm) were acquired. Signal intensity (SI) data were primarily analyzed by CMRtools (Version 2007, Cardiovascular Imaging Solutions Ltd, Cambs, UK), which yields signal intensities (SI ± SD) within a delineated region of interest (ROI) and allows export to other software platforms. A mono-exponential model for the proton signal intensities as function of echo time TE was applied, in order to fit the unknown signal amplitude SI (TE=0), the transverse relaxation rate R2\*, and the constant signal level offset SILO. This was performed according to equation 1 by a Levenberg-Marquardt algorithm:  $SI(TE) =$

$SI(0) \cdot \exp(-R2^* \cdot TE) + SILO$ . In short axis view, the left ventricular myocardium was traced in 90°-quadrants equidistantly demarcating the septal sector from the upper and lower RV junction points as in Figure 1. In each of the quadrants of the interventricular septum, the lateral wall, the anterior wall, and the posterior (inferior) wall, the TE dependent averaged signal intensities were determined. The resulting R2\* rates from the 4 myocardial segments were normalized to the septal R2\* for each patient. The impact of boundary effects on R2\* of the 4 cardiac segments were investigated in selected patients in order to highlight typically underlying origins.



#### **Results**

The segmentation of the cardiac wall resulted in median R2\* of 46, 64, 59, and 68 s<sup>-1</sup> for the septal, anterior, lateral, and inferior (posterior) quadrant, respectively, for all 32 patients. The septal relaxation rate was significantly correlated (p < 10<sup>-4</sup>) with R2\* of the other 3 segments by Spearman rank coefficients of RS = 0.80 (lateral), 0.84 (inferior), and 0.90 (anterior). Patients were divided into two groups (n = 16 each) defined by the septal R2\*: group 1 with R2\* < 50 s<sup>-1</sup> (or T2\* > 20 ms) and group 2 with R2\* > 50 s<sup>-1</sup>. The septal R2\* largely depends from the differentiation between cardiac wall tissue and the blood barrier of the left and right ventricle. The signal intensities from the septum show a mono-exponential pattern, while the lateral cardiac wall exhibits a typical in-phase and out-of-phase behavior with reduced R2\*. This is amplified in an ROI, which was restricted to the cardiac wall / epicardial fat boundary. The posterior (inferior) cardiac wall is close to the liver, which is usually iron overloaded in most patients. Thus, an impact of the relatively high magnetization of the liver tissue due to elevated LIC levels on R2\* of the posterior cardiac wall could be expected, as R2\* depends on magnetic susceptibility differences from local magnetic fields.

#### **Conclusion**

The measurement of MRI-R2\* in the interventricular septum is the least affected method by boundary effects to detect patients with iron overload at risk of developing heart failure.

#### **Key words:**

iron, myocardium, relaxation rate, R2\*, boundary effect