

Non-selective double inversion recovery pre-pulse for flow-independent black blood myocardial scar imaging: optimization of the T1 suppression range

S. A. Peel¹, G. Morton¹, E. Nagel¹, and R. M. Botnar¹

¹Division of Imaging Sciences and Biomedical Engineering, King's College London, London, London, United Kingdom

Introduction & Purpose: MRI late gadolinium enhancement (LGE) using the inversion recovery (IR) sequence is the current gold standard for the assessment of myocardial scar. Although it achieves high contrast between infarct and normal myocardium, there is often poor infarct-to-blood contrast. It has been previously shown that the non-selective double inversion recovery (NS-DIR) technique can provide flow-independent signal suppression over a wide user-defined T₁-range.⁽¹⁾ In this work we examine the effect of: 1) adjusting the T₁ suppression range and 2) imaging at different time points after contrast administration.

Methods: *NS-DIR pre-pulse:* A NS-DIR pre-pulse with two time delays, TI₁ and TI₂, was implemented on a 3T Philips Achieva MR scanner. TI₁ and TI₂ were optimized in simulations by minimizing M_z between T₁min and T₁max for heart rates between 45 and 120bpm at 5bpm intervals. T₁min was set to between 50 and 300ms at 25ms intervals. T₁max was always set to 1400ms.

Phantom experiments: A T₁ phantom (T₁-range=120ms-1730ms) was imaged using the body coil at 3T with the NS-DIR pre-pulse and fast gradient echo (TFE) readout. Images were acquired with the TI₁ and TI₂ times optimised for each T₁ suppression range at different heart rates. The signal-to-noise ratio (SNR) was calculated for each T₁ sample in each of the images.

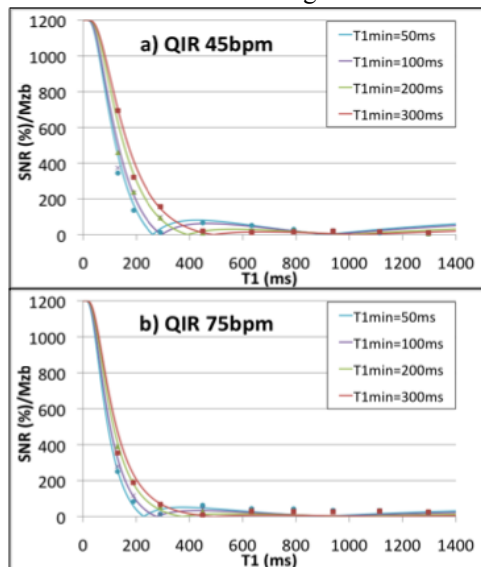


Figure 1: Normalized M_z simulations (lines) and corresponding SNR values (markers) measured in phantom images for TI₁ and TI₂ values optimized for heart rates 45 and 75bpm.

Patient Studies: Three patients with confirmed myocardial infarction were imaged using a 32-channel coil at 3T at 10, 20 and 30 minutes after injection of 0.2mmol/kg of Gadovist. Firstly a breath-hold 2D IR segmented gradient-echo (TFE) sequence was acquired in a short-axis view. Imaging parameters included: spatial resolution=1.3x1.3x10mm, TR/TE=3.5ms/2ms, FA=25°, imaging every two heartbeats and TI chosen using a preceding Look-Locker sequence. Imaging was subsequently repeated with the IR replaced by the NS-DIR pre-pulse with the imaging parameters maintained (except imaging was performed every heartbeat). TI₁ and TI₂ were optimised with a T₁min value of 50, 100, 200 and 300ms according to the patient's heart rate. The TFE factor was adjusted in each scan to achieve a 14s breath-hold.

Results: M_z simulations (fig.1) show the signal characteristics of the NS-DIR sequence for each T₁min value at two heart rates and indicate excellent signal suppression over each T₁-range with corresponding phantom studies in good agreement. Patient images (fig. 2) show that the NS-DIR pre-pulse improves infarct depiction compared with the standard IR-TFE technique and that the level of blood suppression can be controlled by adjusting the T₁min value.

Conclusions: The NS-DIR pre-pulse can be used to suppress blood signal and improve depiction of sub-endocardial infarcts. Adjustment of the T₁min value controls the level of blood suppression. Time post contrast administration has a smaller effect on signal characteristics than T₁ min. **References:** (1) Peel, SA. et al. Proc. ISMRM,18(2010):p3199.

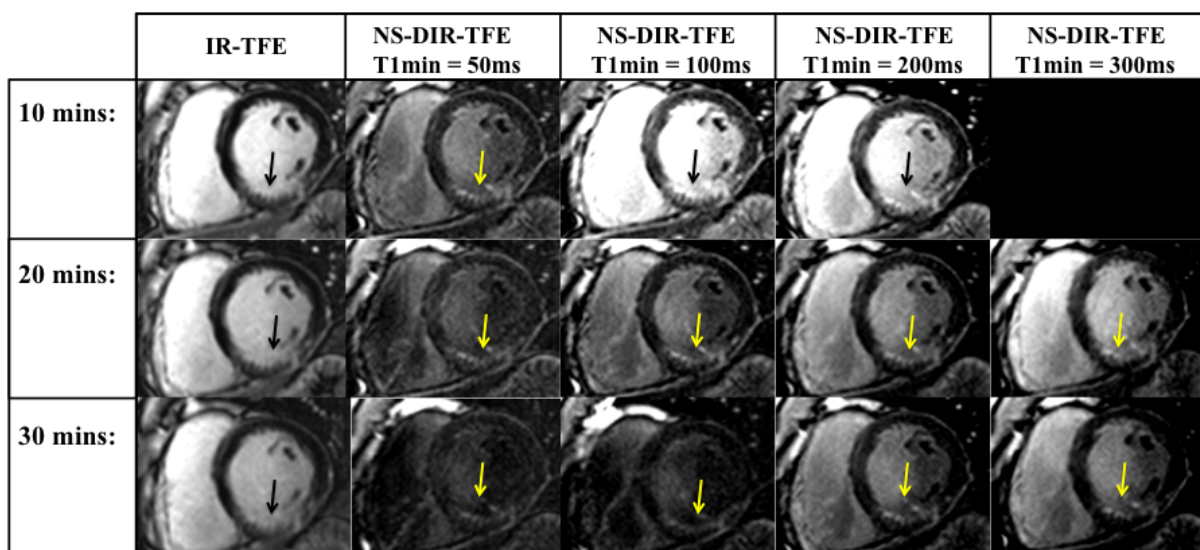


Figure 2: A patient (heart rate = 50bpm) with a sub-endocardial mid-ventricular inferior and inferoseptal infarct (arrows) at 10, 20 and 30 minutes post contrast. There is suboptimal infarct to blood differentiation on IR-TFE images which is improved in NS-DIR TFE images. The level of blood suppression can be controlled by adjusting T₁min.