

## **Diagnostic Capability and Reproducibility of Myocardial Strain Measured by DENSE MRI in Patients with Acute Myocardial Infarction**

K. Kitagawa<sup>1</sup>, H. Miyagi<sup>1</sup>, S. Kato<sup>1</sup>, Y. E. Yoon<sup>1</sup>, M. Nagata<sup>1</sup>, S. Takase<sup>1</sup>, A. Sigfridsson<sup>2</sup>, and H. Sakuma<sup>1</sup>

<sup>1</sup>Radiology, Mie University Hospital, Tsu, Mie, Japan, <sup>2</sup>Center for Medical Image Science and Visualization, Linköping University, Linköping, Sweden

### **Introduction:**

Accurate assessment of regional myocardial dysfunction is important for the evaluation of acute myocardial injury. Displacement ENcoded with Stimulated Echo (DENSE) MRI can provide radial (e1) and circumferential strains (e2) with minimal manual interaction and short processing time. We assessed the hypothesis that myocardial strain measured by DENSE MRI can accurately diagnose the extent of left ventricular (LV) myocardial injury in patients with acute myocardial infarction (AMI).

### **Methods:**

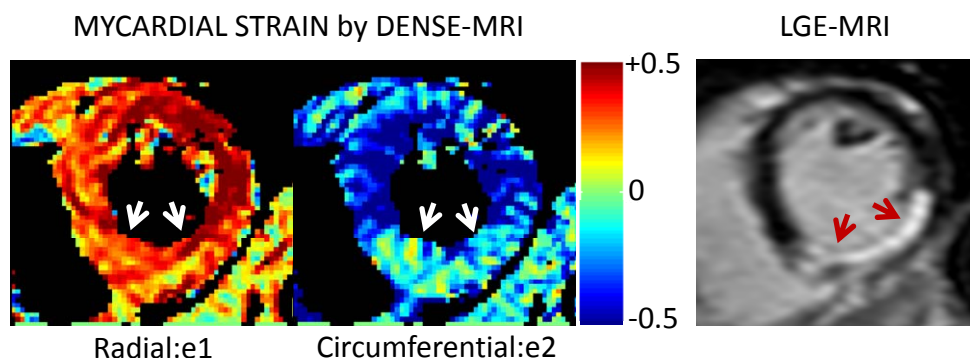
Myocardial Eulerian strains by DENSE MRI were assessed with 1.5T MR scanner and 32 channel coils in 20 patients (64±12 years) with AMI 6±3 days after primary percutaneous coronary intervention (PCI). The DENSE pulse sequence used a segmented EPI approach, consisting of three excitations per cardiac phase and seven read-outs per excitation. Other imaging parameters were: field of view 350 mm, slice thickness 8 mm, acquisition matrix 128x120, reconstruction matrix 240x240, SENSE reduction factor 2, heart phase interval for cine acquisitions 50 ms, TR 8.5-9.9 ms, TE 4.1-4.6 ms. In a 16-segment model of the LV, e1 and e2 were quantified by custom made software using MATLAB and were compared with late gadolinium enhancement (LGE) MRI. The 16 segments were averaged to assess LV global radial and circumferential strain. Intra- and inter-observer reproducibility was tested in the 20 patients.

### **Results:**

DENSE MRI was successfully completed in all subjects. LGE was observed in 105 of 320 segments including 62 segments with subendocardial infarction. Both e1 and e2 were significantly reduced in segments with transmural infarction compared with those without (e1:  $0.13 \pm 0.04$  vs  $0.20 \pm 0.05$ ,  $p < 0.001$ , e2:  $-0.15 \pm 0.06$  vs  $-0.29 \pm 0.10$ ,  $p < 0.001$ ). With a cutoff value of 0.16 for e1, the sensitivity and specificity of DENSE MRI were 74% and 80% for predicting transmural infarction, with area under the receiver operating characteristics curve (AUC) of 0.85. For e2, these values were 84%, 80%, and 0.89, respectively, with a cutoff value of -0.21. The LV global strain showed a good correlation with LV infarct size measured by LGE-MRI (e1:  $R^2 = 0.56$ ,  $p < 0.001$ , e2:  $R^2 = 0.50$ ,  $p = 0.001$ ). Both e1 and e2 showed high intra- and inter-observer reproducibility with intraclass correlation coefficient of  $> 0.9$ .

### **Conclusion:**

In patients with AMI treated with primary PCI, myocardial strain by DENSE MRI can accurately determine the extent of acute myocardial injury. With excellent reproducibility, the assessment of regional and global myocardial strain by DENSE MRI may be highly useful for monitoring functional recovery of LV myocardium in patients after primary PCI.



**Figure:**

Myocardial strain by DENSE-MRI and LGE-MRI obtained from a patient with acute myocardial infarction in the inferior wall. Reduced radial and circumferential strain was clearly demonstrated by DENSE-MRI in the inferior wall presenting LGE.