

# Analysis of segmental myocardial performance in patients after heart transplantation

D. Foell<sup>1</sup>, T. Wengenmayer<sup>1</sup>, B. A. Jung<sup>2</sup>, E. Schilli<sup>1</sup>, A. L. Stroh<sup>1</sup>, C. Bode<sup>1</sup>, J. Hennig<sup>2</sup>, and M. Markl<sup>2</sup>

<sup>1</sup>Cardiology and Angiology, University Hospital Freiburg, Freiburg, Germany, <sup>2</sup>Diagnostic Radiology, Medical Physics, University Hospital Freiburg, Germany

**Introduction:** Regional myocardial function analysis is of high interest in heart transplant recipients. The accurate diagnosis of acute transplant rejection is often difficult since global cardiac function is not a sensitive marker and myocardial biopsy is limited by the sample error. It is known that regional myocardial motion [1], left ventricular (LV) rotation [2], and diastolic function [3] are depressed early on during rejection before global systolic function is reduced. In addition, there is growing evidence that even stable patients after heart transplantation can demonstrate alterations in LV performance due to remodeling within the transplanted heart [4]. Therefore an exact evaluation of LV regional function is crucial for these patients. MRI Tissue Phase Mapping (TPM) allows the quantitative segmental evaluation of myocardial velocities with high resolution and full LV coverage [5]. The aim of our study was to analyze in detail the segmental three-directional LV velocities in patients after heart transplantation (HTX, n=9) without signs of rejection. We compared the results with the data of healthy volunteers (n=20).

**Methods:** 3 short-axis slices (basal, midventricular, apical) were acquired (1.5 T MR system, Sonata, Siemens). A black-blood prepared gradient echo TPM sequence (TR=6.9ms; temporal resolution 13.8ms; spatial resolution 1.3×2.6mm; venc=15cm/s in-plane, 25cm/s through-plane) with prospective ECG- and advanced navigator gating [5], view sharing and first-order flow compensation was used. 9 patients after heart transplantation (age=45±16) and 20 age-matched volunteers (age = 51.3±/ 3.9) were examined (Table 1). Data post-processing (Matlab, The Mathworks, USA) included correction for translational motion and a transformation of the measured three-directional velocities into radial, rotational and long-axis velocities adapted to the LV anatomy. A 16 segment AHA model was used for segmental analysis. Systolic and diastolic peak and time-to-peak (TTP) velocities of radial and longitudinal velocities were derived from the velocity time course of each segment and compared to the data of healthy volunteers in the same segment using an un-paired t-test. Furthermore the difference between apical and basal rotation, the LV velocity twist, was calculated.

**Results:** Patients demonstrated significant alterations in long-axis and radial velocities. In systole, reduced long-axis velocities were prominent in the patients in nearly all segments, reaching significance in basal inferior and antoseptal regions compared to the healthy volunteers (see figure 2A). In contrast, systolic radial peak velocities did not demonstrate significant differences between patients and controls (see figure 2B). Diastolic peak long-axis velocities were reduced in all segments and significantly lower in all basal regions except of the septum (see figure 2A). Furthermore, normal regional diastolic velocity gradients in volunteers (peak long-axis velocity difference in basal lateral vs septal regions = 36%, basal vs apical regions = 203%) were altered in HTX patients (23% and 163%), despite normal global LV function. Diastolic radial velocities were higher in patients after heart transplantation compared to age- matched controls, especially in anterolateral and anteroseptal regions (see figure 2B). TTP systolic and diastolic velocities (not shown) were reduced, whereas magnitude and timing of the velocity twist was not significantly altered in the patients.

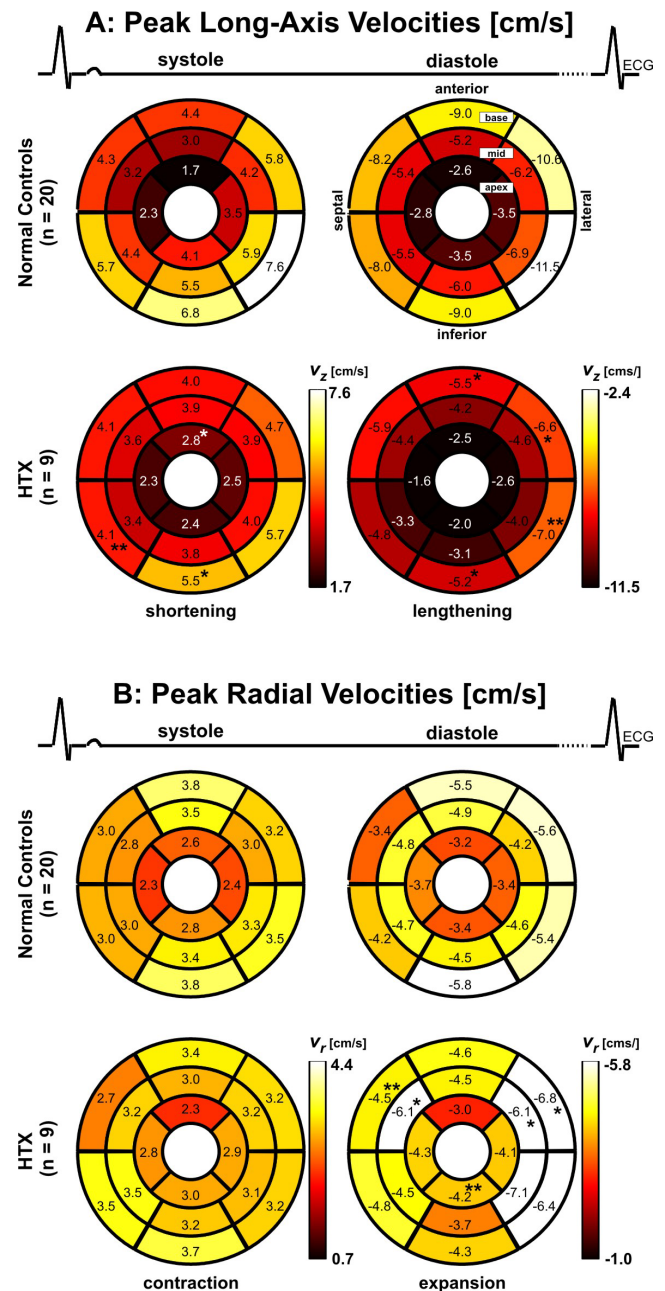
**Discussion:** Transplant recipients demonstrated extensive segmental myocardial motion alterations compared to age-matched controls. These differences were not limited to diastolic motion but included systolic motion components despite normal global LV function. Early systolic long-axis velocity correlates with LV contractility [6]. Therefore the regionally decreased peak long-axis velocities might be an expression of regional remodeling and fibrosis in the transplanted heart [4]. The reduced TTP velocities were explained due to the higher heart rates of the patients. The knowledge of these alterations in regional left ventricular motion in the transplanted heart is essential in order to use myocardial velocities as diagnostic tools in transplant rejection. Therefore TPM might get a sensitive tool for the diagnostic work-up and patient monitoring after heart transplantation.

**Acknowledgements:** Deutsche Forschungsgemeinschaft (DFG), Grant FO 507/3-1, Bundesministerium für Bildung und Forschung (BMBF), Grant # 01EV0706.

**References:** [1] Wu Y L et al, *JACC Cardiovasc Imaging*. 2009, 2(6): 731–741. [2] Hansen DE et al, *Circulation* 1987, 76:998-1008. [3] Yoshida S et al, *J Heart Lung Transplant* 1998, 17:1049-1056; [4] Nozynski J et al. *Transplant Proc* 2007, 39:2833-2840. [5] Jung B A et al. *J Magn Reson Imaging* 2006; 24:1033-39. [6] Mishiro et al, *J Am Soc Echocardiogr*, 12(11):813-20.

	age	heart rate	BP sys	BP dia	EF	LVEDV	LV mass
HTX n=9	45±16	86±12	126±14	80±7	61±7	129±33	154±29
Volunteers n=20	51±4	63±8*	133±14	81±7	57±6	113±26	103±25*

**Table 1:** Characteristics of the patients and volunteers.\*p< 0.05 vs. HTX. Abbreviations: BP: blood pressure, EF: ejection fraction, LV: left ventricular, EDV: end-diastolic volume.



**Fig. 1:** Regional analysis of segmental left ventricular (LV) velocities (AHA 16-segment model). **A: Long-axis motion:** Comparison of segmental peak velocities in systole (shortening) and diastole (lengthening). **B: Radial motion:** Comparison of segmental peak velocities in systole (contraction) and diastole (expansion). All data represent mean values over all volunteers and patients (HTX). \*\* and \* indicate significant differences with p<0.01 resp. p<0.05.