

Noncontrast MR Angiography for Comprehensive Assessment of Abdominopelvic Arteries using Quadruple Inversion-Recovery Preconditioning and 3D balanced Steady-State Free Precession Imaging

I. P. Atanasova^{1,2}, D. Kim¹, R. P. Lim¹, P. Storey¹, and V. S. Lee¹

¹New York University, New York, New York, United States, ²Columbia University, New York, New York, United States

Introduction: Non-invasive assessment of the aortoiliac and the renal arteries is crucial for the management of peripheral arterial disease (PAD). However, given the recently discovered safety concerns associated with gadolinium-based contrast agents and the prevalence of impaired renal function in patients with PAD, noncontrast (NC) MR angiography (NC MRA) is gaining significant interest in clinical practice. Existing peripheral NC MRA techniques [1, 2] are susceptible to motion degradation in the abdomen due to respiration and peristalsis. Inversion-recovery (IR) prepared "time-of-flight" based NC MRA with 3D balanced steady-state free precession (b-SSFP) (IR b-SSFP MRA) readout has been developed for evaluation of renal arteries [3] with promising results, but is inadequate for imaging abdominopelvic arteries due limited craniocaudal coverage. The objective of this study was to develop a NC MRA pulse sequence for comprehensive assessment of the aortoiliac and renal arteries in a single acquisition and assess its feasibility *in vivo*.

Methods: Figure 1 shows schematic diagrams of the pulse sequence. The longitudinal magnetization is preconditioned with 4 IR pulses prior to 3D b-SSFP readout. First, a non-selective (NS) IR pulse is applied with inversion time T_{inflow} to attenuate the background. Second, immediately after the NS IR pulse, a slice-selective (SS) IR pulse overlaying the aorta in a "sagittal" plane is applied to re-invert the aortic blood, from top of the field of view (FOV) to the aortic bifurcation. Third, a SS IR pulse with inversion time T_{null} is applied caudal to the imaging FOV for suppression of inflowing venous spins. Fourth, a short tau IR (STIR) pulse was applied prior to 3D b-SSFP readout, in order to suppress fat and further attenuate the background. Finally, ten linearly increasing ramp-up excitation pulses were used to accelerate the approach to steady state prior to oblique coronal 3D b-SSFP readout. The spatial coverage of arterial inflow from the bifurcation to the distal external iliac is governed by T_{inflow} (i.e., transmit time) and the flow rate of arterial blood. T_{inflow} was selected to achieve a good balance between arterial inflow and background suppression. Assuming mean arterial velocity of 14 cm/s [4], selecting T_{inflow} of 1300 ms predicts 180mm coverage of fresh arterial inflow distally from the bifurcation point. In most patients, this distance should be sufficient to visualize the entire length of the iliac arteries. T_{null} was determined empirically because the efficacies of the IR pulses outside of the FOV are unknown. Imaging was performed on a 1.5T system (Avanto, Siemens) equipped with two body coil arrays and spine coil array for signal reception. NC MRAs were obtained using quadruple IR 3D b-SSFP oriented in an oblique coronal slab with respiratory bellows triggering (20% end expiration). Imaging parameters included: FOV 400x400 mm², voxel size 1.3x1.3x1.7 mm³, 60-80 partitions, nominal slice thickness 1.7mm, slice resolution 65%, TR 1 respiratory cycle, TE 1.7ms, FA 90°, BW 1042 Hz/pixel, 2 shots per partition, GRAPPA factor 3 with 24 reference lines, and scan time ~ 6 min. IR parameters included: NS IR with T_{inflow} 1300ms; 20-60mm thick IR pulse oriented in oblique sagittal plane with TI 1280ms; 200 mm SS IR pulse positioned inferiorly to the FOV with T_{null} 500ms; STIR with TI 160ms. Four volunteers (3 male, 1 female, average age 39y.) were imaged using the aforementioned protocol. One patient (female, age 66) referred for contrast-enhanced (CE) MRA for suspected claudication was imaged with the NC MRA sequence prior to undergoing CE MRA with a standard clinical protocol.

Results: In all subjects, MRAs exhibited excellent arterial conspicuity from the renal to the external iliac arteries with optimal background suppression (Fig. 2). In the patient, both NC MRA (Fig. 2b) and CE MRA (Fig. 2c) exhibited good depiction of mild infrarenal aortic atherosclerosis and left internal iliac artery origin stenosis. These results demonstrate that NC MRA using four IR pulses and b-SSFP acquisition is feasible and provides comprehensive assessment of the abdominopelvic arteries.

Conclusion: The proposed non-contrast MRA pulse sequence provides high spatial resolution (1.3x 1.3 x 1.7mm³) visualization of the abdominopelvic arteries within clinically feasible scan times of ~ 6 min. This technique is an extension of the previously described IR b-SSFP MRA method designed for renal MRA. The main advantage of the proposed NC MRA compared to IR b-SSFP MRA is that spatial coverage of arterial visualization was approximately doubled for essentially the same transmit times for arterial inflow. This was made possible by the application of the sagittal SS IR pulse that reinverts the aorta. In patients with severe disease and critically slow flow, it may be necessary to increase T_{inflow} to allow sufficient arterial inflow coverage from the aortic bifurcation point, at the expense of slightly brighter background signal. Further evaluation in a clinical population is necessary to assess the diagnostic utility of this pulse sequence.

References: [1] Miyazaki, Radiology 2003; 227:890 [2] Edelman, MRM 2010; 63: 951 [3] Katoh M, et al., Kidney International 2004, 66: 1272-1278 [4] Atanasova, ISMRM 2010: 3783;

Acknowledgments: NIH R01-HL092439, AHA 0730143N.

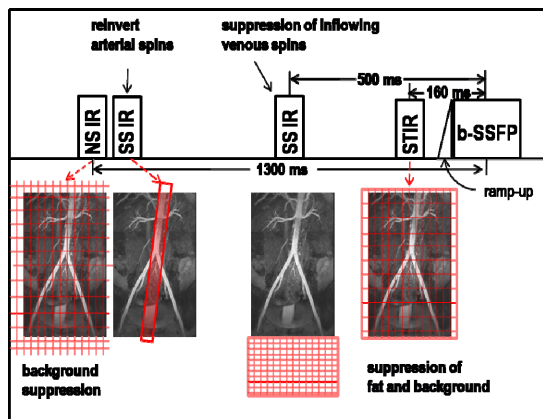


Figure 1. Pulse sequence diagram illustrating timing of IR pulses.

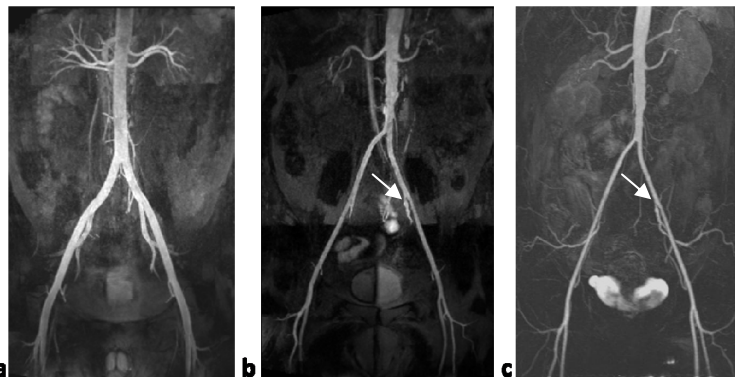

Figure 2. a) NC MRA of male volunteer. b) NC MRA and c) CE MRA of a patient. Both NC MRA and CE MRA exhibited good depiction of infrarenal aortic atherosclerosis and left internal iliac artery origin stenosis (arrows).