

Preoperative mapping of autogenous saphenous veins in patients with PAOD and femorodistal bypass grafting: Prospective comparison of peripheral MR angiography using a blood pool contrast agent with ultrasound and intraoperative findings

A. M. Jah-Kabba¹, G. M. Kukuk¹, D. R. Hadizadeh¹, A. Koscielny², F. Verrel², H. H. Schild¹, and W. A. Willinek¹

¹Department of Radiology, University of Bonn, Bonn, NRW, Germany, ²Department of Vascular Surgery, University of Bonn, Bonn, NRW, Germany

Aim of the study:

To evaluate the diagnostic value of steady state images as an adjunct to peripheral MR angiography (MRA) with a blood pool contrast agent (BPCA) in patients with peripheral artery occlusive disease (PAOD) for mapping of autogenous saphenous veins before femorodistal graft surgery for limb salvage and to compare the results with duplex ultrasound (US) and intraoperative findings.

Introduction:

It has been demonstrated that - in contrast to standard first pass MRA – MRA in the equilibrium phase performed with a blood pool contrast agent allows to visualize also the veins as an adjunct to arterial imaging without the need of a second contrast injection¹⁻³. This may enable venous mapping of autogenous saphenous veins in patients with PAOD who are scheduled for subsequent femorodistal bypass grafting.

Materials and Methods:

38 patients with PAOD (21 men, 17 women; mean age, 71 years [range, 44-88 years) with peripheral arterial disease underwent first-pass and steady-state MR angiography after a single injection of the BPCA Gadofosveset Trisodium on a 1.5 T whole body MR system. Institutional ethics committee approval and written informed consent were obtained. Steady state images were assessed by 1 reader in order to identify great saphenous veins and to determine venous diameters on axial MPR images at three levels: below the saphenofemoral junction(1), mid thigh(2) and 10 cm above the knee joint(3). Duplex ultrasound was performed by an independent reader providing diameter measurements at the same levels. In addition, vessel useability/non-useability (patency; diameter range: 4-8 mm/occlusion; diameter <4 or >8 mm) were determined intraoperatively by the vascular surgeon during subsequent femorodistal bypass surgery.

Results:

38 patients with a total of 76 assessable legs were included. Mean venous diameters for MRA/US were (5.4±2.62/5.5±2.8) mm for level 1, (4.7±2.7/4.6±2.9) mm for level 2 and (4.4±2.2/4.5±2.3) mm for level 3, respectively, without significant differences between the modalities (p=0.24/0.81/0.52). Subsequent surgery was performed in 27/38 patients. A suitable saphenous vein was diagnosed in 24/24 and non-useability was diagnosed in 3/3 of the 27 patients based on MRA/US, respectively. Intraoperative assessment confirmed useability and non-useability in the 24 and 3 patients. In the latter, prosthetic grafts were alternatively used for reconstruction.

Conclusion:

Mapping of autogenous saphenous veins as an imaging adjunct to peripheral MRA with a BPCA is feasible without significant differences as compared to duplex ultrasound. It correctly allows selection of candidates for autogenous venous graft surgery and may replace time-intensive venous ultrasound in the preoperative work-up of patients with PAOD.

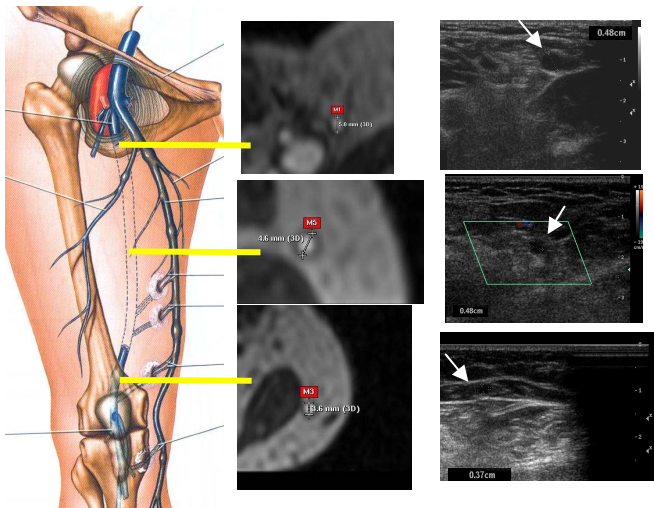


Fig. 1: Comparison of venous diameters a determined by MRA using the BPCA Gadofosveset (images in the center) and by US (images on the right) in the great saphenous vein at level 1, level 2 and level 3, respectively.

References

- 1 Ruehm SG et al. AJR Am J Roentgenol 2000; 174:1127-1135.
- 2 Fraser DG et al. Radiology 2003; 226:812-820.
- 3 Willinek WA et al. In: Leiner T et al.; Clinical Blood Pool MR Imaging, Springer, Heidelberg 2008. 251-258.