

## Quantitative T1, T2 and T2\* Mapping of Carotid Artery Normal Wall and Atherosclerotic Plaque

G. Mihai<sup>1</sup>, S. Giri<sup>2</sup>, T. P. Sharkey-Toppen<sup>2</sup>, S. V. Raman<sup>1</sup>, S. Rajagopalan<sup>1</sup>, and O. P. Simonetti<sup>1</sup>

<sup>1</sup>Cardiovascular Medicine, The Ohio State University, Columbus, OH, United States, <sup>2</sup>Biomedical Engineering, The Ohio State University, Columbus, OH, United States

**Introduction:** Atherosclerosis, the leading cause of mortality and morbidity globally manifest secondary to multiple mechanisms that promote plaque instability (1). Multi-contrast magnetic resonance imaging (MRI) has been validated against histology as being able to assess biological features of plaque vulnerability (2-4). However, plaque characterization with multi-contrast MRI (5-7) is a time consuming process that is subject to interpretative bias, image acquisition issues and as such is difficult to implement in clinical settings. Identification of plaque composition is predicated by tissue's specific biophysical MR properties (T1, T2, T2\*,etc.). These intrinsic tissue properties can be identified in MR images and displayed as MR quantitative relaxation time maps that have the fundamental information needed to characterize plaque morphology (8). In this work, we evaluate the feasibility of obtaining quantitative T1, T2\* and T2 relaxation times from carotid artery wall in normal subjects and from plaque in subjects scheduled for endarterectomy. Our hypothesis is that the global relaxation times values reflect plaque composition and could be integrated in clinical management of disease without the bias and subjectivity associated with visual interpretation of relaxation-time weighted images.

**Methods:** Nine normal subjects (5 females, mean age=46.2±11 years) and 15 symptomatic patients (3 females, mean age=60.8±11.5 years) scheduled for carotid endarterectomy were imaged using a 3T whole body MRI system (MAGNETOM Verio, Siemens Healthcare, Erlangen, Germany) and an 8-element (4 left and 4 right) custom built carotid coil. A standard three-plane localizer was used to identify the carotid arteries, while a three dimensional (3D) time-of-flight (TOF) angiographic sequence was used to identify both right and left common carotid bifurcation and stenosis location. Acquisitions to map longitudinal relaxation time T1 ( gradient echo: TR/TE/TI= 900/7.2/ 100,150,230,400,700,880ms, in plane resolution=0.5x0.5 mm<sup>2</sup>, averages=6), transverse relaxation time T2 (spin echo: TR/TEs=3R-R interval/ 7, 35, 63ms, image resolution=0.5x0.5 mm<sup>2</sup>, averages = 3) and T2\* (gradient echo: TR/TEs=740/2.7,7.5,12.3,17,21.8 ms, image resolution=0.4x0.4 mm<sup>2</sup>, averages=2) were performed in a single, 3 mm thick slice perpendicular to the common carotid (CC) in normals and in the region with maximum stenosis in patients (either CC or internal carotid artery). Quantitative time relaxation maps were computed off-line by mono-exponential fitting of MR images obtained with different inversion times (T1) and different echo times (T2 and T2\*). A region of interest encompassing the vessel wall (normal subjects) and vessel wall and plaque (diseased subjects) was selected and relaxation times T1, T2 and T2\* were obtained.

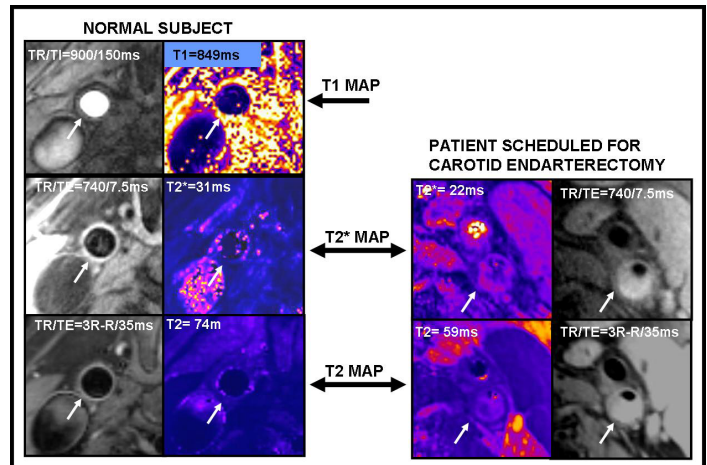
**Results:** Good quality MR images resulted in interpretable T2 and T2\* relaxation maps in all of subjects. In one subject motion of the neck between different TI acquisitions (for T1 maps) resulted in slight mis-registration of the arterial wall. Figure 1 shows examples of cropped MR images and maps obtained in a normal and a diseased subject. Both T2 and T2\* were significantly shortened (p<0.05) in diseased subjects compared to normals; T1 maps were not obtained in patients. A summary of the global relaxation times is presented in Table 1

Normal Subjects			Atherosclerotic Subjects		
T1(ms)	T2(ms)	T2* (ms)	T1(ms)	T2(ms)	T2* (ms)
N=4	N=9	N=9	N=0	N=4	N=15
685.9±166	69.1±6.6	26.6±2.5	*	59.2±1.5	18.8±4.8

**Table 1.** MRI relaxation times.

**Discussion:** Quantitative mapping of MRI relaxation-times in the carotid arteries of normal and diseased subjects is feasible. The global values obtained for T1 and T2 in the carotid wall are in the expected range of previously reported values (9) for atherosclerotic plaque components. The difference in quantitative relaxation times between normal and diseased subjects most likely reflects relaxation time differences between plaque and normal vessel wall tissue. In conclusion, an extended study of normal and atherosclerotic diseased subjects to determine normal age and sex specific relaxation times and to correlate relaxation time constants to biological measures of plaque vulnerability has the potential to generate an objective, unbiased, quantitative approach to define atherosclerosis disease severity.

**References:** 1. Naghavi, M., et al. *Circulation*, 2003; 108: 1772-8. 2. Yuan, C., et al. *Circulation*, 1998; 98:2666-71. 3. Cai, J.M, et al. *Circulation*, 2005; 112:3437-44. 4. Takaya, N., et al. *J Magn Reson Imaging*, 2006; 24: 203-11. 5. Yuan, C., et al., *Circulation*, 2001; 104: 2051-6. 6. Cai, J.M., et al., *Circulation*, 2002; 106:1368-73. 7. Fayad, Z.A. and V. Fuster, *Ann N Y Acad Sci*, 2000; 902: 173-86. 8. Raman, S.V. et al. *JACC Imaging* 2008; 49-57. 9. Sun, B., et al., *Magn Reson Med*, 2008; 59: 174-80.



**Figure 1.** MR images (white/grey) and corresponding relaxation maps (colored, signal intensity is directly related to the value of the relaxation times) in a 39y old normal subject (left) and a 62y old patient (right). Arrows point to the CC in the normal subject and to ICA in the patient. In patient's images the plaque obstructs the lumen and shows inhomogeneity (due to different plaque components) in T2\* and T2 maps