

Volumetric Whole-Heart Three-Directional Tissue Phase Mapping of the Heart at 3T

A. Lutz¹, A. Bornstedt¹, P. Etyngier², R. Mancke³, W. Rottbauer¹, G. Nienhaus⁴, and V. Rasche¹

¹University Hospital of Ulm, Ulm, BW, Germany, ²Medisys Research Lab, Philips Healthcare, Suresnes, France, ³Philips Research NA, Briarcliff Manor, United States, ⁴Karlsruhe Institute of Technology, Karlsruhe, Germany

Introduction: Up to now, tissue phase mapping (TPM) of the myocardium is normally performed by two-dimensional velocity encoded MRI, acquired in apical, equatorial and basal view orientation. Thus, huge parts of the myocardium are not covered. The aim of this work is to acquire a three-dimensional TPM data set covering the whole myocardium of the heart in a reasonable acquisition time.

Materials and Methods: The MR examination was performed in 10 healthy volunteers on a 3T whole-body MR scanner (Achieva, Philips Medical Systems, The Netherlands) with a 32 [2 x 2 x 4] channel phased array cardiac coil. To ensure better blood suppression, the acquisition of the heart was split into three subsequently acquired slabs covering the apical, equatorial and basal segments. Data was acquired with a segmented gradient echo velocity-encoded black-blood imaging sequence. Parallel imaging (SENSE factor of 4x2) was used for ensuring reasonable data acquisition times. The imaging parameters (exemplarily for 60bpm) were as: TR/TE = 6.4 ms/4.3 ms, acquisition time = 3:42 min, spatial resolution = 3 x 3 mm², slice thickness = 6mm with 3mm slice overlap, 3 k-lines per segment, flip angle = 15 °, VENC = 20 cm/s in all 3 encoding directions, and 25 heart phases. The radial (towards the center of the heart), longitudinal (towards the apex of the heart) and circumferential velocity curves were calculated by an in-house developed MATLAB program.

Results: Figure 1 displays the radial, longitudinal and circumferential velocity-time curves for each apical slice (1-7), equatorial slice (8-14) and basal slice (15-21).

Radial (fig. 1a): at early systole, a central movement of the heart can be observed in all slices with highest radial velocities in the equatorial regions. For apical slices, a single distinct outward motion is observed during diastole. Towards the basis, the outward motion occurs earlier and some oscillation of the myocardium appears. During maximal outward motion in the apex, a maximal central motion is observed in the basal segment.

Longitudinal (fig. 1b): at the beginning of systole, apical, equatorial and basal slices move towards the apex of the heart during the first half of rapid ejection. This motion is stronger for the basal than for the apical slices. At the end of rapid ejection phase, the velocity of this downward motion is decreased to a plateau in the basal slices, whilst equatorial and apical slices are reaching small negative values, indicating that these slices are slowly moving back towards the base of the heart. During diastole, all slices move back toward the basis of the heart. This motion is much more pronounced for the basal than for the apical slices. Subsequently, a short motion in opposite direction occurs in all regions.

Circumferential (fig. 1c): The circumferential motion starts with a rotation in counter-clockwise direction in all slices at the beginning of rapid ejection. In the middle of rapid ejection, the basal and equatorial slices reverse their direction, thus moving in clockwise direction, whereas the most apical slices still rotate counter-clockwise. This results in the twisting of the left ventricle. At the beginning of diastole, the apex starts rotating clockwise, whereas the basal slices rotate counter-clockwise. Afterwards, all slices are performing a small wave of first clockwise and then counter-clockwise motion.

All volunteers show a similar behavior of motion for the different slice locations.

Discussion and Conclusion: These results nicely demonstrate the rather strong variation of the radial, longitudinal and circumferential myocardial contraction motion over different short axes regions of the heart. Similar results were reported by different researchers before, but derived from only a few slices of the heart [1, 2]. The obtained result demonstrates the feasibility of 3D myocardial tissue phase mapping for ensuring a gapless coverage of the myocardial motion. In combination with parallel imaging, this proposed technique enables whole-heart coverage in a reasonable acquisition time, thus providing deeper insight into details of myocardial motion.

References: [1] Codreanu et al. J Cardiovasc Magn Reson 2010, 12:48 [2] B Jung et al. J Magn Reson Imaging 2006; 24: 1033-1039

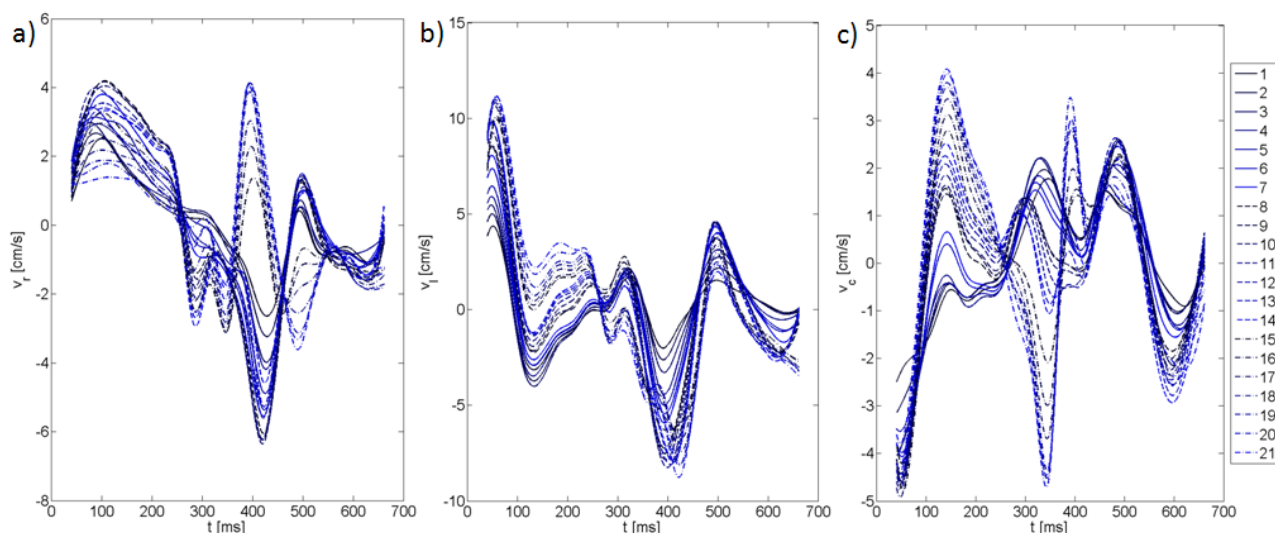


Figure 1: Radial (left), longitudinal (mid) and circumferential (right) velocity-time curves for the whole heart (apical slices: 1-7, equatorial slices: 8-13, basal slices: 14-21).