

## Dynamic contrast enhanced MRI of the Achilles enthesis in spondyloarthritis

R. Hodgson<sup>1</sup>, P. Wright<sup>2</sup>, A. J. Grainger<sup>2</sup>, P. J. O'Connor<sup>2</sup>, P. Helliwell<sup>3</sup>, D. McGonagle<sup>3</sup>, P. Emery<sup>3</sup>, and M. D. Robson<sup>4</sup>

<sup>1</sup>LMBRU, University of Leeds, Leeds, Yorkshire, United Kingdom, <sup>2</sup>Leeds Teaching Hospitals NHS Trust, <sup>3</sup>University of Leeds, <sup>4</sup>University of Oxford

### Introduction.

Involvement of the Achilles enthesis is common in spondyloarthritis with inflammatory changes including increased vascularity in the tendon and bone. Dynamic contrast enhanced (DCE) MRI has been shown to be useful for the assessment of the musculotendinous junction in mechanical or degenerative Achilles tendinopathy as it correlates with histological markers of tendon disease and is responsive to treatment [1,2]. The aim of this work was to investigate DCE-MRI of the Achilles enthesis in spondyloarthritis. The objectives were to determine whether DCE-MRI measurements of the Achilles tendon near the enthesis (i) are increased in symptomatic SpA, (ii) correlate with bone changes at the enthesis and (iii) are related to power Doppler ultrasound (PDUS) findings.

### Methods.

23 patients with SpA and symptoms relating to the Achilles tendon and 13 healthy volunteers were studied. Dynamic contrast enhanced MRI was performed using a 3D SPGR 5.2/2.5/25° sequence with an acquisition time of 10s per 3D data set. The echo time was chosen so that fat and water in the bone marrow of the calcaneus were in phase. 25 images were acquired before (4 datasets), during and after the intravenous administration of 0.1 mmol/kg Gd DOTA at 4 ml/s. 3D elliptical regions of interest were positioned in the Achilles tendon at the level of the superior calcaneus and in the bone marrow of the adjacent calcaneus. The relative early enhancement rate (RER) in each ROI was calculated over 10s. Ultrasound was performed by a musculoskeletal radiologist and the presence of power Doppler changes was recorded. Differences in DCE-MRI measurements from the Achilles tendon between the patient and control groups, and between patients with and without PDUS changes were compared using the 2 tailed t-test. Correlations in the RER of tendon and bone marrow were tested with Pearson's correlation coefficient.

### Results.

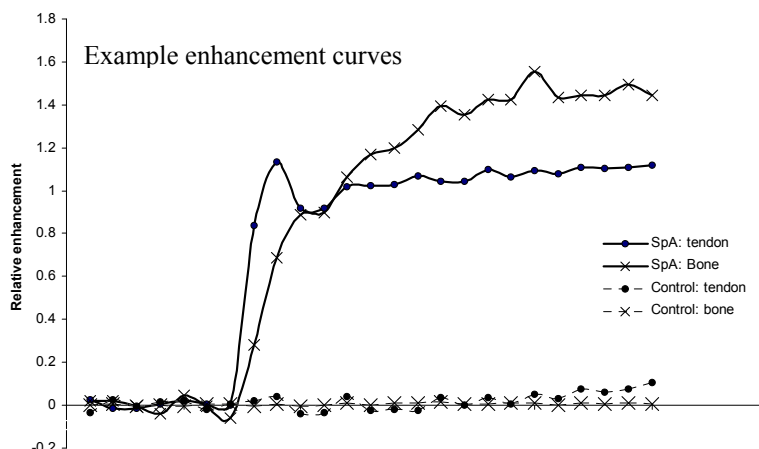
RER for SpA patients and controls.

	SpA patients	Controls	p-value
Tendon	0.28 (0.31)	0.07 (0.02)	<b>0.003</b>
Bone	0.08 (0.11)	0.03 (0.04)	0.073

mean (st dev)

RER for SpA patients with and without PDUS

	PDUS +ve	PDUS -ve	p-value
Tendon	0.45 (0.70)	0.07 (0.08)	<b>0.001</b>



The Pearson Correlation coefficient between early enhancement rates in bone and tendon was 0.59 ( $p < 0.001$ ).

### Discussion.

This study showed RER in tendons in symptomatic SpA patients was greater than that in healthy controls. This is similar to previously demonstrated changes in patients with mechanical or degenerative tendinopathy [2]. It also showed a link between power Doppler ultrasound changes and the DCE-MRI RER. RER depends strongly on vascularity while power Doppler directly visualises blood flow in larger vessels so a link between them is expected; such a relationship has also been shown in mechanical tendon disease [1].

There was a moderate correlation between RER in the Achilles and RER in the adjacent calcaneus. There was also a trend for increased RER in SpA patients, although this did not reach statistical significance. This is in keeping with known association between tendinopathic change and osteitis at the Achilles enthesis organ in SpA [3].

In conclusion, these results show the potential of DCE-MRI to assess the Achilles enthesis in SpA.

[1] Richards PJ et al. Skeletal Radiol 2010;39:509-21

[2] Shalabi A et al. Acta Radiologica 2002;43:198-206

[3] Benjamin M et al. Adv Exp Med Biol 2009;649:57-70