

Changes in high spectral and spatial resolution MR images of tumor tissue due to locally induced hyperthermia

S. Foxley¹, X. Fan¹, J. River¹, M. Zamora¹, E. Markiewicz¹, S. Sokka², and G. S. Karczmar¹

¹Department of Radiology, University of Chicago, Chicago, IL, United States, ²MR-HIFU, Philips Healthcare, Andover, MA, United States

INTRODUCTION: Locally induced hyperthermia is generally used clinically to treat small, often superficial tumors. Micro-electrode measurements demonstrate that both temperature changes as well as consequent physiological responses are heterogeneously distributed within the tumor (1). While single point and multifocal measurement techniques, such as needle probes, provide useful information, these measurements are invasive and cannot routinely provide high resolution images of hyperthermic response across a significant volume of tissue. MRI overcomes these problems by allowing for non-invasive measurement of both temperature change (2) as well as physiologic changes including oxygenation (3). In this work we used high spectral and spatial resolution (HiSS) MRI to measure relative changes in water resonance frequency and peak width due to mild hyperthermia. To do this, a novel method was developed to induce hyperthermia during MRI in a rodent tumor model.

METHODS: Ten experiments (2 bench experiments and 8 MRI hyperthermia experiments) were performed using male nude mice bearing AT6.1 rodent prostate tumors inoculated in the hind leg. Local hyperthermia (5-6° C) was induced during MRI experiments in the tumor bearing mouse leg using fiber optic guided light from a 250 W halogen bulb. Bench experiments were performed as a gold standard measurement of temperature change with needle probes inserted subcutaneously and 1.5 mm in to the tumor. Temperature was measured every 2.5 minutes for 6 time points with the light off and 6 with the light on. MRI experiments followed the same time course with approximately the same temporal resolution; 6 HiSS datasets were acquired with the light off followed by 6 with the light on. HiSS data were acquired using a multi-gradient echo pulse sequence. B_0 maps and water spectrum peak width maps were constructed for each time point. Temperature time series data from bench experiments and B_0 and peak width data were fit on a voxel-by-voxel basis with equation 1: $s(t) = A(1 - e^{-at})$. Maps of 'A' were produced for B_0 and peak width time series data, signifying the maximum change in both due to heating, over regions of interest including muscle, tumor, tumor rim, and tumor center.

RESULTS: Eq. [1] provided excellent fits to bench experiments and B_0 time series data ($R^2 > 0.995$), justifying its use with HiSS data. Figure 1 shows a typical (a) spin echo image of a tumor bearing hind leg as well as the corresponding overlain 'A' maps for (b) B_0 (A_{B_0}) and (c) water peak width (A_{PW}). Mean positive and negative A_{PW} over muscle, tumor rim, and tumor center were all significantly different from baseline ($p < 0.0003$, by a two-tailed, unpaired Student's t-test). The mean negative A_{PW} over tumor rim (-12.9 ± 4.5 Hz) was significantly larger [$p = 0.04$, by analysis of variance (ANOVA)] than in normal muscle (-7.9 ± 1.4 Hz). Mean positive changes in A_{PW} were somewhat larger in tumor rim (10.0 ± 3.2 Hz) than in muscle (7.0 ± 2.3 Hz), with modest significance [$p = 0.08$, by ANOVA]. The mean standard deviation over A_{PW} for each ROI was determined over all experiments as a measure of the spatial heterogeneity of the response to hyperthermia. The mean standard deviation was significantly larger in the tumor rim (26.1 ± 8.2 Hz) than in the tumor center and in normal muscle (14.6 ± 5.7 Hz, $p = 0.001$; and 16.2 ± 4.3 Hz, $p = 0.005$; respectively, by ANOVA).

DISCUSSION: These results demonstrate robust changes in water resonance peak width produced by mild, transient hyperthermia. Changes detected using high spectral and spatial resolution MRI are spatially heterogeneous and may reflect heterogeneous changes in tumor temperature, tumor blood flow, and/or tumor blood oxygenation. The results suggest that the response to hyperthermia, combined with functional MRI, could be used as a diagnostic technique to detect and characterize cancers. In addition, imaging could be used to guide the development of improved hyperthermia protocols to produce the desired change in oxygenation across the tumor.

REFERENCES:

1. Kelleher DK, *et al.*, *Int J Hyperthermia* 1995;11(2):241-255
2. Rieke V, *et al.*, *J Magn Reson Imaging* 2008;27(2):376-390
3. Foxley S, *et al.*, *Magn Reson Med* 2009;61(2):291-298

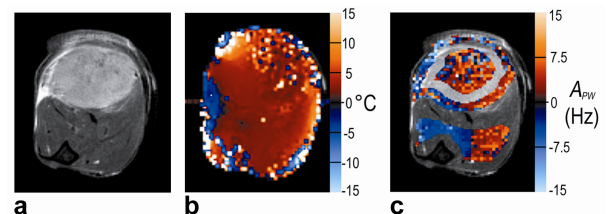


Figure 1. (a) Spin echo image of typical tumor bearing hind leg for anatomic reference. In images (b-c), red scale indicates increasing positive changes and blue scale, negative changes, according to the label on the respective y-axis. (b) A_{B_0} map reflecting the maximum change in temperature in each voxel over the course of an experiment. Changes are typically 5°C. (c) A_{PW} values, reflecting maximum absolute changes in water peak width (in Hz) in tumor rim, tumor center, and normal muscle ROI's.