

MR Microimaging of ex-vivo prostate tissue at 16.4T

G. Cowin¹, N. D. Kurniawan¹, P. Sved^{2,3}, G. Watson⁴, and R. Bourne⁵

¹Centre for Advanced Imaging, The University of Queensland, Brisbane, Queensland, Australia, ²Department of Surgery, Faculty of Medicine, University of Sydney, Sydney, New South Wales, Australia, ³Department of Urology, Royal Prince Alfred Hospital, Sydney, New South Wales, Australia, ⁴Department of Anatomical Pathology, Royal Prince Alfred Hospital, Sydney, New South Wales, Australia, ⁵Discipline of Medical Radiation Sciences, Faculty of Health Sciences, University of Sydney, Sydney, New South Wales, Australia

Introduction: Current gold standard for prostate cancer identification is by histopathology of biopsy tissue¹. However, current clinical MRI methodologies are limited by resolution and contrast to achieve a level of absolute characterisation provided by tissue biopsy. Therefore, the development and analysis of a high-resolution MRI method to produce definitive microscopic tissue information is crucial for future non-invasive identification and monitoring the progression of cancer in both clinical and experimental studies. Diffusion² and T_2 -weighted³ imaging have potential sensitivity to detect prostate cancer tissues. In this work, we present an investigation using diffusion tensor MR micro-imaging at 16.4 T to measure the high-spatial resolution (40 μ m) ex-vivo water diffusion properties of fixed prostate tissue samples.

Materials & Methods: Prostate tissue was collected from 5mm slices of formalin fixed radical prostatectomy specimens with a 3mm core punch. Samples were immersed in 0.2% Magnevist and imaging was performed on a 16.4T Bruker AV700 magnetic resonance microimaging system (5 mm solenoid RF coil, Micro2.5 gradient set: 2.5 G/cm/A). The imaging sequence suite includes: 3D spin echo DTI sequence at 40 μ m isotropic resolution, $\delta/\Delta = 2/12$ ms, $b=1500$ s/mm² with 6 directions. 3D gradient echo T_2^* -weighted imaging sequence using TR/TE = 40/6ms, pulse angle = Ernst angle ($\sim 30^\circ$), 8 scans at 20 μ m isotropic resolution. T_2 maps were reconstructed from 3D-fast spin echo sequence using TR=500ms, 8 echos, 4 scans at 40 μ m isotropic resolution. Diffusion parametric images were calculated using the program DiffusionToolkit0.5 (www.trackvis.org).

Results: High-resolution MRI (40 μ m isotropic voxels) of fixed prostate tissue clearly demonstrates distinct microscopic diffusion environments and tissue architectures, which are consistent with a similar tissue type seen on light microscopy. The most restricted diffusion environment is the secretory epithelial cell layer (voxel mean diffusivity, $D = 0.6 \pm 0.1 \times 10^{-3}$ mm²/s). Diffusion in the fibromuscular stromal matrix surrounding secretory epithelium is relatively less restricted ($D = 1.5 \pm 0.2 \times 10^{-3}$ mm²/s). Since the voxel dimension is approximately 2-3 times the thickness of the epithelial cell layer the actual mean diffusivity value in the layer (secretory cells and intercellular spaces) would be expected to be significantly lower than the measured voxel value. The T_2 -map shows different contrast to the diffusion image with the T_2 value of the epithelial cell layer is $\sim 24 \pm 2$ ms and the fibromuscular matrix 15 ± 3 ms.

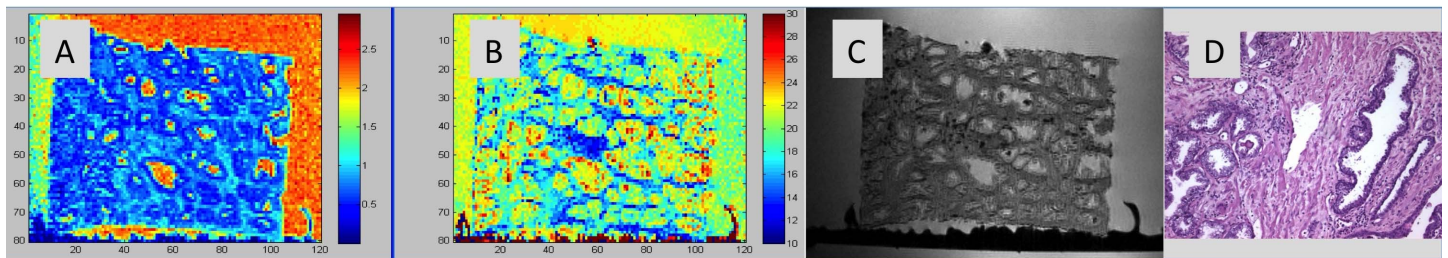


Figure 1: MR microscopy of prostate tissue corresponding slices of (A) diffusion map, (B) T_2 map (ms), (C) high resolution T_2^* image and (D) H&E microscopy of a similar type of prostate tissue sample used in A-C.

Conclusion: MR-microimaging demonstrates the likely physical basis of tissue compartmentation inferred from low spatial resolution in vivo imaging. In normal prostate glandular tissue, high spatial resolution diffusion imaging demonstrates the presence of three compartments with distinct properties of diffusion and cell density. This finding supports a biexponential fitting of in vivo DWI data, which previously been interpreted as indicating the presence of two distinct diffusion environments in normal prostate tissue¹. In addition, T_2 -weighted imaging could provide further differentiation of tissue types shown in diffusion MRI, whereas the ultra-high resolution T_2^* image produced superb tissue structural information approaching detail quality of histological images.

Reference:

1. Xu JQ *et al.* Magnetic Resonance Diffusion Characteristics of Histologically Defined Prostate Cancer in Humans. *Magnetic Resonance in Medicine* 2009; 61(4): 842-850.
2. Kim JH, *et al.* Apparent Diffusion Coefficient: Prostate Cancer Versus Noncancerous Tissue According to Anatomical Region. *Journal of Magnetic Resonance Imaging* 2008; 28(5): 1173-1179.
3. Lim HK *et al.* Prostate Cancer: Apparent Diffusion Coefficient Map with T2-weighted Images for Detection-A Multireader Study. *Radiology* 2009; 250(1): 145-151.