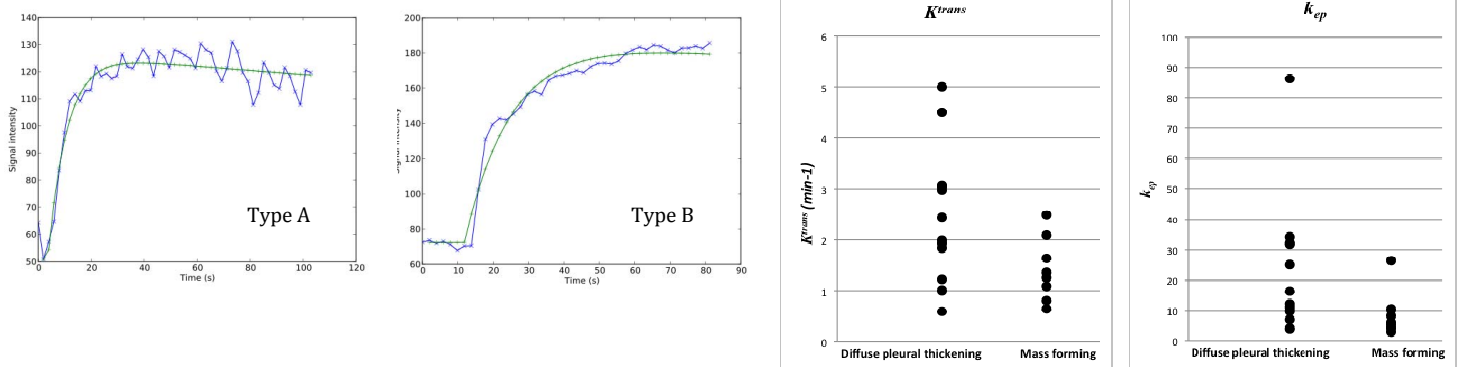


Preliminary result of pharmacokinetic parameter evaluation in malignant pleural mesothelioma: Correlation with histology and growth type.

H. Mamata^{1,2}, R. R. Gill^{1,2}, J. Tokuda^{1,2}, R. F. Padera^{2,3}, R. E. Lenkinski^{2,4}, W. G. Richards^{2,5}, T. R. Tilleman^{2,5}, D. J. Sugarbaker^{2,5}, and H. Hatabu^{1,2}

¹Radiology, Brigham and Women's Hospital, Boston, MA, United States, ²Harvard Medical School, Boston, MA, United States, ³Pathology, Brigham and Women's Hospital, Boston, MA, United States, ⁴Radiology, Beth Israel Deaconess Medical Center, Boston, MA, United States, ⁵Thoracic surgery, Brigham and Women's Hospital, Boston, MA, United States

Background and purpose: Malignant pleural mesothelioma (MPM) is a deadly disease of pleura that is known to have strong association with asbestos exposure [1]. Average survival from the diagnosis of the disease is 9 to 17 months [2] and epithelioid histological subtype has better prognosis than non-epithelioid (sarcomatoid or biphasic/mixed subtype) [3]. Although histological subtype shows slight difference in survival, treatment of the disease does not differ. The survival depends on resectability of the lesion. The role of imaging in the MPM management is to determine extension of the disease and its resectability, in some extent; it may also provide information of histological characteristics, for example by diffusion-weighted imaging [4]. In this study, we investigated dynamic contrast enhanced (DCE) MRI in MPM and correlated pharmacokinetic parameters (K^{trans} , v_e , k_{ep}) with histological subtypes and growth type. **Materials and Methods:** Twenty MPM patients (16 males, 4 females, average age 64.9 years old) with MPM were enrolled in the study. The study was conducted under the guideline of the Internal Review Board and a written informed consent was obtained from all the participants. All patients underwent MRI study including T2-weighted axial half-Fourier acquisition single-shot turbo spin-echo (HASTE) images, pre and post contrast T1-weighted axial, sagittal, and coronal volumetric interpolated breath-hold examination (VIBE) images, and 3D turbo FLASH perfusion imaging. The DCE-MRI study was performed with shallow free breathing. All MRI studies were performed on a 3T-superconducting magnet (Siemens Trio, TIM system, Erlangen, Germany) using a body array coil. After the imaging study, histological diagnoses were made in all cases by core biopsy or pleurectomy. MRI parameters were as follows: T2-weighted HASTE (TR/TE=1200/100msec, FOV=400mm, 320x320, 1 excitation, BW=780kHz, FA=150, ETL=256, 5.5mm slice thickness/1.6mm inter slice gap, scan time=6min); T1-weighted VIBE (TR/TE=3.4/1.3msec, FOV=400mm, 260x320, 1 excitation, BW=505kHz, FA=10, 4mm slice thickness/0mm inter slice gap, scan time=1.7min); 3D turbo FLASH (TR/TE=500/1.6msec, FOV=400mm, 192x180, 1 excitation, BW=360kHz, FA=10, coronal orientation, Temporal resolution=4sec, scan time=4min, Gd-DTPA iv. 0.1 mmol/kg). Time-intensity curves were fitted, and then K^{trans} , v_e , and k_{ep} were calculated based on the two-compartment model [5]. After blinded data analysis, correlation with tissue histology as well as growth type of the lesion, e.g., mass forming vs. diffuse pleural thickening, was performed. Mann-Whitney U test was performed for statistical analysis. **Results:** The histology included 10 epithelioid subtype MPMs, 10 non-epithelioid (3 sarcomatoid and 7 biphasic) MPMs. We observed 2 different types of time-intensity curves: one with steep increase of intensity and gradual decrease or plateau after reaching the peak intensity (Type A), and the second with relative moderate increase of intensity without reaching the peak (Type B). Type of time-intensity curve did not correlate with tissue histology. Fifty percent of each epithelioid and non-epithelioid (sarcomatoid and biphasic) MPM showed Type A, and the rest of 50% of each subtypes showed Type B. Any of pharmacokinetic parameters did not correlate with tissue histology. There was no statistic difference between epithelioid and non-epithelioid subtypes with any of the parameters. However, when analyzed by growth type, K^{trans} was statistically significantly smaller ($p=0.045$) in mass-forming MPMs than diffuse pleural thickening MPMs. k_{ep} was also statistically significantly smaller ($p=0.022$) in mass-forming MPMs than diffuse pleural thickening MPMs. Average K^{trans} for Type A was $2.7 \pm 1.1 \text{ min}^{-1}$, for Type B was $1.1 \pm 0.5 \text{ min}^{-1}$. Average k_{ep} for Type A was $25.4 \pm 21.0 \text{ min}^{-1}$, for Type B was $4.8 \pm 1.4 \text{ min}^{-1}$. Type B MPMs had larger percentage of mass-forming lesions (63%) while Type A MPMs only had 25%. On the other hand, Type A MPMs included 75% of diffuse pleural thickening MPMs. Average age of Type B MPM was younger (60 y/o) than Type A MPM (67 y/o). Average age of mass-forming MPM was also younger (61 y/o) than diffuse pleural thickening MPM (67 y/o). Growth type did not correlate with histological subtype. **Discussion:** Pharmacokinetic parameters and time-intensity curves were evaluated by histological subtype and growth type of MPM. None of the parameters or time-intensity curves correlated with histological subtype, although epithelioid subtype is considered to have better prognosis than sarcomatoid or biphasic subtypes. Majority of diffuse pleural thickening MPM showing Type A curve, higher K^{trans} and k_{ep} values may suggest that diffuse pleural thickening MPM is rather composed of inflammatory processes than tumor cells, while pharmacokinetic parameters in mass-forming MPM reflecting actual tumor characteristics. Also relative younger age was associated with mass-forming MPM as well as MPM with Type B curve. Mass-forming MPM tends to spare very little functioning lung volume, which may have an effect on patients' prognosis and survival. Further investigation in larger cohort including long-term survival observation would be warranted after this preliminary study. Limitation of this study is that location of ROI did not match with the biopsy site. There is always an uncertainty about true histology of the area that measurement was performed. MPM is not a localized disease, without clear demarcation, and different tissue histology cells may scatter around in biphasic subtype MPM, which makes analysis of any kind difficult. **Conclusion:** Pharmacokinetic parameters or time-intensity curve types do not correlate with histological subtypes of MPM, however, growth type correlates with pharmacokinetic parameters, time-intensity curve type, and age. Pharmacokinetic parameters and time-intensity curve type of diffuse pleural thickening MPM may reflect inflammatory nature of those lesions rather than tumor cells.



References: [1] Robinson BW, et al. N Engl J Med 2005. [2] Sugarbaker DJ, et al. J Thorac Cardiovasc Surg 1999. [3] Tsao AS, et al. J Clin Oncol 2009. [4] Umeoka S, et al. AJR 2010. [5] Tofts PS. J Magn Reson Imaging 1997.

*This research is supported by NIH R25 CA089017-06A2. NIH 5R21 CA11627-02.