

## Time-Frequency Analysis of In Vivo MRS of the Breast Improves Cancer Detection

F. Shic<sup>1</sup>, A. P. Lin<sup>2</sup>, P. Stanwell<sup>2</sup>, S. Ramadan<sup>2</sup>, E. Gombos<sup>2</sup>, and C. Mountford<sup>2</sup>

<sup>1</sup>Child Study Center, Yale University School of Medicine, New Haven, CT, United States, <sup>2</sup>Center for Clinical Spectroscopy, Brigham and Women's Hospital, Boston, MA, United States

**Introduction:** The presence of a choline resonance at 3.23ppm has been shown by several groups to be a diagnostic marker for invasive breast cancer *in vivo*<sup>1</sup>. In our previous studies MRS was undertaken prior to biopsy<sup>2</sup>. However, in this study the patients had biopsies and biopsy clips prior to the MRS, causing blood in the lesion to degrade the local field homogeneity. The use of spectral windowing methods, such as the short-time Fourier transform (STFT), may help in the identification of choline by providing access to both frequency and time information simultaneously.

**Objective:** To determine if the STFT of single voxel proton MRS can help to improve additional diagnostic information in addition to that of the choline resonance at 3.23ppm.

**Patients:** 25 women (ages 35-62) with suspected masses in the breast were recruited under IRB approval for this study. All subjects underwent MRI guided vacuum-assisted surgical core needle biopsy immediately prior to MRS exams. Pathological results were obtained and used as the gold standard for comparison.

**Data Acquisition:** Single voxel proton spectroscopy was acquired on a 3T MR scanner (TIM Trio, Siemens, Germany) using a 7 channel breast coil (InVivo Milwaukee). Voxel size and location were chosen following contrast enhanced T1 weighted imaging to identify lesions in patients. Localized zero- and first-order shimming was accomplished via automated B0-field mapping (Siemens AG, Erlangen, Germany) followed by manual adjustment of zero-order shim gradients to achieve width of water at half-maximum of better than, or equal to 30 Hz. Following frequency adjustment water-selective suppression was optimized using the WET-technique. The data was acquired using PRESS localization using a TR/TE of 2000/135 ms with voxel sizes of 0.5 – 4.9 cm<sup>3</sup> and 128 to 256 averages depending on the size of the voxel. A non-suppressed water reference was acquired with each voxel.

**Data Processing:** All data was anonymized prior to analysis and blinded to the observers. *Conventional spectral analysis* was completed on the MR scanner (SYNGO, Siemens) where automated post-processing was applied including water referencing, apodization, zero filling, Fourier transformation, phase correction, baseline correction. The same dataset is displayed in two windows using 0-4 ppm and 2.5 – 4.0 ppm ranges in order to ascertain spectral quality and detection of choline signal, respectively. *Time-frequency analysis* was conducted similarly with the STFT using a sliding Gaussian window with width=160ms and  $\sigma=40$ ms. In both cases determination of tumor malignancy was made by experienced clinical spectroscopists with access to either conventional analyses, or conventional analyses + STFT.

**Results and Discussion:** Of the 25 exams, the conventional spectral analysis (e.g. see Figure 1, left) provided 100% sensitivity and 60% specificity with 100% positive predictive value and 76.5% negative predictive value when compared with pathological results. Simultaneous time-frequency analysis (e.g. see Figure 1, right) provided 90% sensitivity, 93% specificity, a PPV 90%, and NPV 93%.

**Conclusion:** The use of spectral windowing techniques that provide simultaneous access to both time and frequency information in 1H MR spectra may provide additional diagnostic information for aiding the clinical decision making process. Our results suggest that the specificity of determining the malignancy of breast tumors via 1H MRS is aided by the use of the STFT. Future work will explore the parameters and visualization methods that will provide the greatest insight for clinicians and researchers.

**References:** (1) Mountford, C. et al. *NMR Biomed* **2009**, 22, 54-64. (2) Stanwell, P. et al. *European Radiology* **2005**, 15, 1037-1043.

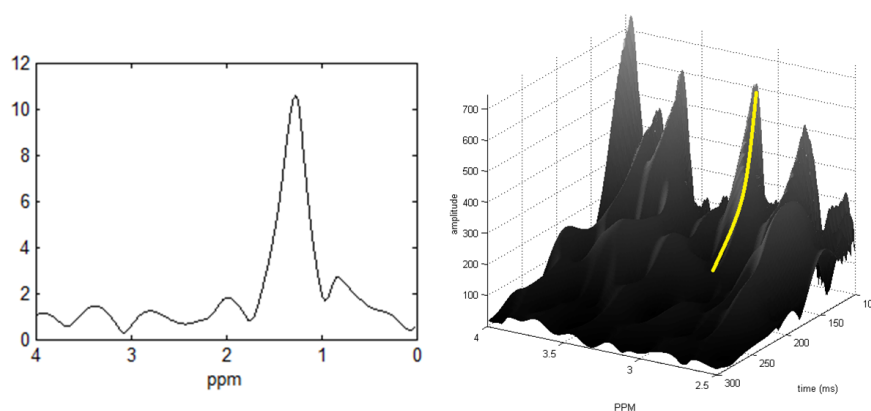


Figure 1. Left: Conventional Fourier Transform of 1H Breast MRS; Right: STFT of the same voxel