

Normal Variability in the Quantitative Assessment of Breast Tissue by MRI

A. Szary¹, S. Aliu¹, S. Suzuki¹, C. Klifa¹, D. Wisner¹, E. Proctor¹, B. Joe¹, and N. Hylton¹

¹Department of Radiology and Biomedical Imaging, UCSF, San Francisco, CA, United States

Purpose: Dynamic contrast enhanced MRI (DCE-MRI) is an essential and evolving tool in breast cancer diagnosis. Appropriate diagnosis is dependent on accurate differentiation between normal parenchymal background enhancement and enhancing tumor. Though DCE-MRI boasts high sensitivity in detection of breast cancer, it demonstrates only moderate specificity. Given this limitation, further study is needed to better understand the range and variability of normal fibroglandular tissue with DCE-MRI and complementary techniques such as diffusion weighted imaging (DWI). Thus, the purpose of the study is to evaluate the normal variability of breast tissue by MRI in order to improve diagnostic accuracy.

Methods: After human subjects approval and informed consent, a prospective study of 19 healthy premenopausal female volunteers ages 21 to 45 who underwent two breast DCE-MRI scans within a 72 hour period (n=15) or at the same menstrual phase in two consecutive months (n=4) was performed. 16 subjects reported a regular menstrual cycle, while three reported irregular cycles. Data was acquired during the follicular phase of the menstrual cycle to limit the effect of hormonal fluctuation. Imaging was performed using a 1.5 Tesla MRI scanner and bilateral 8-channel array breast coil. DCE-MRI data was acquired using a 3D T1 weighted fast gradient recalled echo sequence to obtain a pre-contrast image, early post-gadolinium scan (1 min 50 sec), and late post-gadolinium scan (9 min 8 sec). One subject was omitted due to poor scan quality. In addition, DWI images were obtained using an echo planar sequence in 10 patients. Right and left breast images from each subject were then analyzed by drawing a region of interest around each breast to create a map of breast tissue. A fuzzy c-means algorithm was subsequently used to segment the breast map into clusters representing fat or fibroglandular tissue in order to quantify breast volume, fibroglandular tissue volume, and percent enhancement (PE) (1). Mean values of PE and apparent diffusion coefficient (ADC) were computed from DCE-MRI and DWI data respectively, averaging over the whole fibroglandular tissue volume. Variability and distribution differences of the above parameters were subsequently assessed using the coefficient of variability and paired two tailed t-tests respectively.

Results: Individual subject variability between visits (intra-subject) demonstrated the lowest range for breast volume (1-11%, mean 5%). Mild intra-subject range in variability was demonstrated for fibroglandular tissue volume (1-39%, mean 11%). Moderate range in variability was seen for both PE (0-50%, mean 20%) and ADC values (0-51%, mean 16%). No significant difference in these parameters per subject between visits was seen. In addition, no significant change in measurements between right and left breasts for any parameter was identified. Furthermore, no meaningful correlation of fibroglandular tissue volume and PE was identified for either visit. Breast volume variability amongst all subjects between visits (inter-subject) was 10% for breast volume, 22% for fibroglandular tissue and PE, and 23% for ADC.

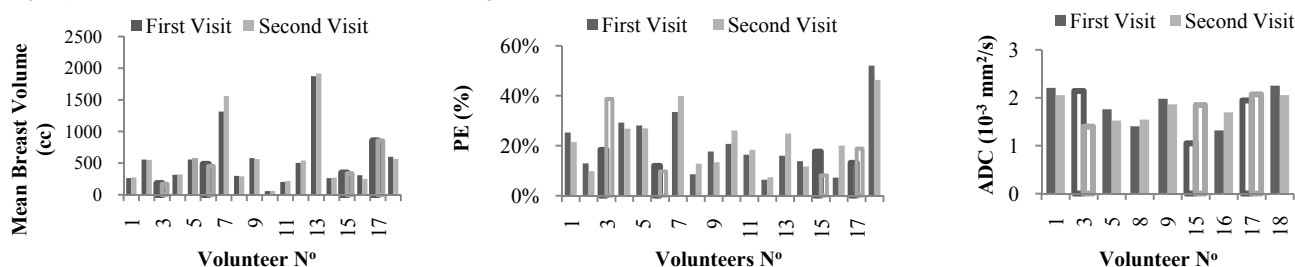


Figure 1: Intra and inter-subject variability with regards to quantitative mean breast volume, PE, and ADC values.

Conclusion: Normal quantitative breast MRI parameters including breast volume, fibroglandular volume, percent enhancement, and apparent diffusion coefficient demonstrate a mild to moderate, though non-significant, range of variability in individual subjects between visits when controlling for hormonal fluctuation. These findings serve as a preliminary reference for normal breast tissue MRI variability in subjects between scans and may help differentiate treatment changes from normal variability in patients receiving follow up breast MRI imaging.

Additionally, though further study is necessary, knowledge of normal variability of background parenchymal enhancement may also provide initial guidance in interpretation of breast MRIs and lead to improved specificity in breast cancer diagnosis.

References: 1. Klifa, C., et al., *Magnetic resonance imaging for secondary assessment of breast density in a high-risk cohort*. Magnetic Resonance Imaging, 2010. **28**(1): p. 8-15