

# Improved lesion conspicuity on contrast enhanced breast MRI at 3 Tesla using linear vs. radial-centric k-space ordering

B. N. Joe<sup>1</sup>, D. Wisner<sup>1</sup>, V. A. Arasu<sup>1</sup>, S. Suzuki<sup>1</sup>, V. S. Deshpande<sup>2</sup>, B. Chang<sup>1</sup>, G. Laub<sup>2</sup>, and N. M. Hylton<sup>1</sup>

<sup>1</sup>Dept of Radiology and Biomedical Imaging, UCSF, San Francisco, CA, United States, <sup>2</sup>Siemens Medical Solutions USA, Inc, San Francisco, CA, United States

## Introduction

Radial-centric ordering of k-space has been used to minimize the effects of minor motion artifact at breast MR but may cause undesirable blurring of fine detail and decreased lesion conspicuity that is clinically apparent on high resolution breast MR examinations at 3T. Linear ordering of k-space theoretically should result in better lesion conspicuity but has the potential disadvantage of sensitivity to motion artifact. The purpose of this study was to evaluate lesion conspicuity and level of detail in patients scanned with both radial-centric and linear ordered k-space techniques on separate days to determine which protocol is better for the clinical purpose of breast cancer screening.

## Methods

Eight patients with a suspected or known breast mass were prospectively recruited to participate in this HIPAA-compliant study approved by our institutional review board. Patients underwent bilateral breast MR on two separate days either using a segmented radially ordered centric or segmented linear ordered k-space protocol. **MR Technique:** In the segmented radial-centric ordered acquisition, 16 k-space lines (lines per fat suppression pulse) were acquired starting at the center of k-space (ky-kz) after each fat suppression pulse, and progressed outwards radially. In the segmented linear ordering, 16 k-space lines were acquired in a linear interleaved manner in the partitions direction after each fat suppression pulse. All partitions were acquired for each ky line before the in-plane phase encoding gradient was incremented. Premenopausal patients were scanned within the same phase of the menstrual cycle. One pre-contrast and two post-contrast 3min. axial VIBE scans were acquired for dynamic (and simultaneously high-resolution) T1 imaging of bilateral breasts on a wide-bore 3T Magnetom Verio (Siemens Medical Solutions) with a Sentinelle 8-channel breast coil. Contrast agent (Magnevist, Berlex) was injected using a power injector at 1.2 ml/sec with the start of the first post-contrast scan. The imaging parameters were as follows: imaging time = 3 min., resolution =  $0.73 \times 0.73 \times 1.6 \text{ mm}^3$ , TR/TE = 4.3 ms/2.18 ms, flip angle = 9 deg., readout bandwidth = 540 Hz/pixel.

**MR Image Assessment:** Three experienced radiologist readers independently reviewed the post-contrast linear and radial-centric ordered breast MR exams for all patients at one sitting blinded to MR exam and technical parameters. Linear vs. radial-centric images were presented randomly side-by-side on two monitors by a nonradiologist researcher who asked readers to state which side (left or right) ranked better or "no difference" if the two sets of images were equal. The researcher then scored '1' if linear was ranked better, '-1' if centric was ranked better, and '0' if linear and centric ranked the same. For 6 of 8 patients with a visible enhancing mass, peak signal enhancement ratio (SER) and SER total enhancing tumor volume was measured for both linear and radial-centric ordered studies as an objective measure of degree of contrast enhancement (similar to subjective lesion conspicuity rating). One patient was excluded for bulk motion artifact precluding accurate SER measurements.

## Results

For lesion conspicuity, linear ordered post contrast images ranked better than radial-centric ordered images 79% (19/24) of the time. Radial-centric ranked better only 8% (2/24) of the time and linear and radial-centric were equally ranked 13% (3/24) of the time. For level of detail, linear ordered ranked better 75% (18/24) of the time while radial-centric ranked better 25% (6/24) of the time. Individual reader rankings are shown in Fig. 1. Motion artifact was noted on the linear ordered images 58% (14/24) of the time, on radial-centric images 21% (5/24) of the time, and no motion artifact was noted 21% (5/24) of the time. Overall image quality was ranked better for linear 42% (10/24) of the time, better for centric 50% (12/24) of the time and equal 8% (2/24) of the time.

Quantitative analyses showed an increase in peak signal enhancement ratio (SER) with linear ordering compared with radial centric ordering of k-space in 4 of 5 patients (Fig. 2a). SER total enhancing tumor volume increased from centric to linear across all patients (Fig. 2b), but the sample size was insufficient to statistically test an alpha of 0.05.

## Discussion

Linear ordering of k-space ranked better than radial-centric ordering for lesion conspicuity and level of image detail on post-contrast T1 breast MR images based on qualitative analyses by breast imaging radiologists. Similarly, quantitative analyses of signal enhancement ratio showed increased peak SER in 4/5 patients and increased SER total enhancing volume in 5/5 patients for linear versus radial-centric ordered k-space images, although sample size was insufficient for statistical analysis. More motion artifact was noted with linear k-space ordering but overall image quality was ranked similarly between linear and radial-centric. Radiologists should be aware of these tradeoffs when deciding upon a linear vs. radial-centric approach to post-contrast breast MR imaging for cancer evaluation.

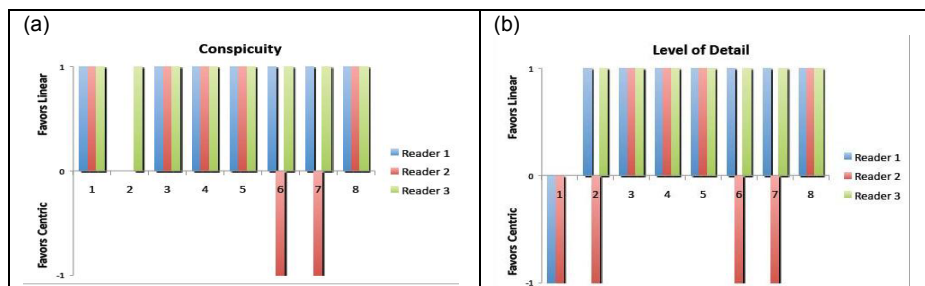


Fig. 1 Individual reader rankings for **lesion conspicuity (a)** and **level of image detail (b)** comparing linear vs. radial-centric ordered images. Ranking of 1 indicates preference for linear, -1 indicates preference for radial-centric and 0 indicates no difference between the two. There was overall reader preference for linear ordered images for both lesion conspicuity and level of detail.

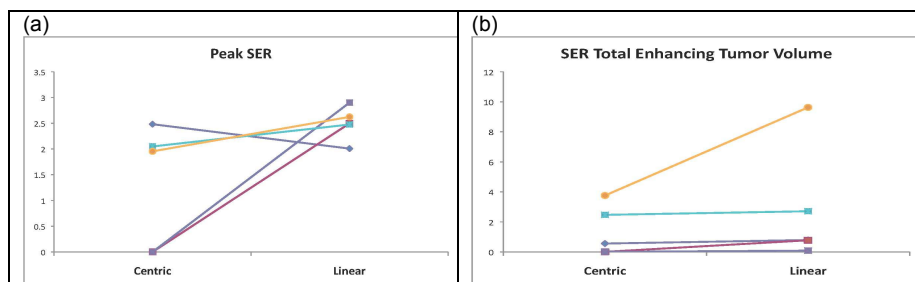


Fig. 2 **Peak SER (a)** and **SER Total Enhancing Tumor Volume (b)** comparison for radial-centric ("Centric") vs. linear ("Linear") ordered k-space for 5 patients with visible enhancing lesions. In 4 of 5 patients, peak SER increased with the linear ordered k-space protocol. In 5 of 5 patients, total enhancing tumor volume increased with the linear ordered k-space protocol. Sample size was insufficient to statistically test an alpha of 0.05.