

# Identifying prostate brachytherapy seeds at MRI: A study in phantom

A. Fatemi-Ardekani<sup>1</sup>, and J. Borg<sup>1</sup>

<sup>1</sup>Radiation Medicine Program, Princess Margaret Hospital, Toronto, Ontario, Canada

## Introduction

Conventionally, post-implant CT scans identifies prostate brachytherapy implant seeds locations. The dosimetric quality of the brachyseed implant evaluated based on its locations respect to prostate and rectal wall using MRI. Post-implant evaluation of prostate brachytherapy using MRI has met with some difficulties due to the uncertainty associated with seed localization despite its excellent anatomical delineation. The correlation between CT and MRI has some variability and time consuming [1]. The goal of our current work was to use SWI phase images for identification of prostate brachytherapy seeds. Using MRI alone to identify seeds will eliminate the need for CT scan at one-month post implant and eliminate the variability of the correlation.

## Materials and Methods

A prostate gel phantom containing five inactive dummy brachyseeds (Advantage I-125<sup>TM</sup> Seeds, IsoAid, Florida, U.S.A) each has central cross section area of 3.6 mm<sup>2</sup>. It was assessed using CT, and MRI. Imaging was done using a GE Signa 3T HD MRI system (GE Healthcare, Milwaukee, WI). Imaging parameters for SWI were: 512x384 (zero filled to 512x512), FOV=10 cm, ASSET factor=2, TE/TR=20/42 ms, FA = 15°, RBW = 80Hz/pixel, spatial resolution = 0.3 x 0.3 x 2.0 mm. Both original magnitude (Fig.1C) and phase images were collected. The optimum TE for maximum contrast to noise ratio (CNR) in filtered phase images theoretically was determined according to [Eqn.1].

$$\frac{dCNR}{TE} = (e^{-\frac{TE}{T2^*}} - \frac{1}{T2^*} \times TE \times e^{-\frac{TE}{T2^*}}) = 0 \rightarrow TE = T2^* \quad [1]$$

The original phase images were unwrapped by using 64 x 64 central homodyne high pass-filter (Fig.1A). And finally, the areas of brachytherapy seeds were correlated with CT and SWI filtered phase image (Fig.2).

## Results and Discussion

Brachytherapy seed as confirmed by CT (Fig.1B), were easily identified in the phantoms on the filtered SWI phase (Fig.1A) images. The mean area for the 5 seeds, as measured on CT and SWI filtered phase images, was 3.5±0.5 mm<sup>2</sup> and 3.8±0.6 mm<sup>2</sup>, respectively (Fig.1). There appeared to be linear relationship in seeds area (Fig.3) as determined by SWI filtered phase compared to CT (R<sup>2</sup>=0.8). The dipole effect, surrounding seed, causes blooming in filtered phase images. This explains why seed area appears larger on SWI filtered phase images compared to CT. Although both CT and MRI both suffer from partial voluming effects the blooming effect is not related. The correlation between CT and MRI shows better confidence in our interpretation that SWI does not only replicate CT findings but also shows the effect is from brachytherapy seed. The presence of background field variations and dipole effect as a result of paramagnetic nature of seeds are the major source of phase image artifacts. This can be reduced using simple high pass filtering to remove low spatial frequency phase variation [2]. Using 64 x 64 central homodyne filter (Fig.3) generate the best estimate of seed area (3.7 mm<sup>2</sup>) as a result of minimal phase image artifacts. With the improved resolution, SNR and proper filtering on high field MRI systems, SWI phase images can be used to confirm prostate brachytherapy seeds on conventional MRI without using CT.




Figure 1. (A) SWI corrected phase image, (B) CT, (C) T2\* Weighted magnitude image.

## References:

- [1] S. D. Thomas, K. Wachowicz, and B. G. Fallone, "MRI of prostate brachytherapy seeds at high field: A study in phantom," *Medical Physics*, vol. 36, no. 11, p. 5228, 2009.
- [2] J. Neelavalli, Y.C.N. Cheng, J. Jiang, and E.M. Haacke, "Removing background phase variations in susceptibility-weighted imaging using a fast, forward-field calculation," *Journal of Magnetic Resonance Imaging*, vol. 29, 2009.

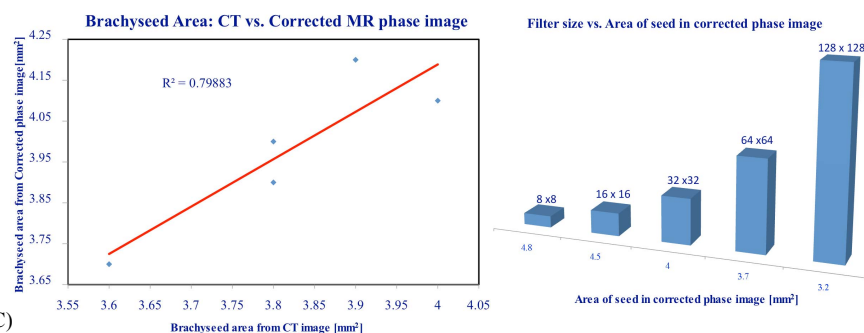


Figure 2. Brachytherapy seeds area correlation between CT and SWI corrected phase image

Figure 3. Brachytherapy seed area in corrected phase vs. filter size