

# The Effect of Fat Suppression on ADC Values in Murine Liver with Variable Degrees of Fibrosis

S. W. Anderson<sup>1</sup>, J. A. Soto<sup>1</sup>, E. Tang<sup>1</sup>, and H. Jara<sup>1</sup>

<sup>1</sup>Radiology, Boston University Medical Center, Boston, MA, United States

**Purpose:** The purpose of this work was to determine if, in the absence of hepatic steatosis, the use of fat suppression pulses results in effects on ADC values and whether these effects vary based on degrees of fibrosis in a murine model of hepatic fibrosis such that this could be considered a potential confounding effect in deriving ADC values of the liver.

**Methods:** Imaging experiments were performed using 11.7T MRI. 17 male C57BL/6 mice were divided into a control group (n=2) fed normal chow and an experimental group (n=15) fed a diet containing 3, 5-dicarbethoxy-1, 4-dihydrocollidine (DDC) to induce hepatic fibrosis. The experimental diet was continued for a total duration of 16 weeks and mice were sacrificed intermittently throughout this period for imaging. During imaging, formalin fixed *ex vivo* liver specimens were placed in phosphate buffered saline (PBS) and temperature was controlled at 23.5°C. Within the larger 15mm vial containing the liver specimen and PBS, a 6mm vial containing PBS, free from contamination from hemorrhage, was placed for use as an internal reference standard. For diffusion weighted MRI (DWI), a multi-slice spin echo pulsed field gradient (PFG) acquisition (TE=10ms, TR=2000ms) was utilized with b-values of 0, 270, and 560 s/mm<sup>2</sup>. This was completed both with and without frequency selective fat suppression. Parametric ADC maps were generated for images acquired both with and without fat suppression. Subtraction images created through the subtraction of the fat suppressed ADC maps from the non-fat suppressed ADC maps were constructed. Five representative regions of interest (ROIs) were placed on liver on the non-fat suppressed parametric ADC map; these ROIs were transferred to the fat suppressed ADC maps as well as the subtraction image in identical locations. In addition, ROIs were placed on the internal reference vial of PBS. ADC values of both liver and PBS on non-fat suppressed and fat suppressed ADC maps as well as the difference based on the subtraction image were recorded.

Subsequent to the imaging experiments, the liver specimens were embedded in paraffin and serial sections of 5µm were cut. Sections were stained with hematoxylin and eosin as well as Masson's trichrome stains. A board certified pathologist reviewed the specimens to evaluate the extent of steatosis using a semi-quantitative scheme ranging from 0-3 based on content of lipid vacuoles in liver parenchyma (0=<5% of parenchyma containing lipid vacuoles, 1=<33% of parenchyma containing lipid vacuoles, 2=33-66% of parenchyma containing lipid vacuoles, 3=>66% of parenchyma containing lipid vacuoles). Livers with any degree of steatosis were excluded from analysis. The degree of fibrosis was assessed using a scale ranging from 0-4 (0=none, 1=portal fibrosis, 2=periportal fibrosis or rare septa, 3=septal fibrosis and architectural distortion, 4=widespread fibrosis, cirrhosis). In addition to the subjective scoring, the trichrome stained specimens were digitized and digital image analysis (DIA) was used to determine the degrees of hepatic fibrosis, expressed as percentage area of fibrosis of the liver specimens.

Mean ADC values of liver specimens and the internal reference vial containing PBS were compared between images acquired with and without fat suppression. Differences in the liver ADC values with and without fat suppression were compared to the degrees of hepatic fibrosis assessed subjectively as well as by DIA; Pearson correlation coefficients (R) were derived using linear regression analyses.

**Results:** Limited degrees of steatosis were seen using the DDC diet to induce hepatic fibrosis; only 4 of 15 experimental mice were excluded for analysis based on the presence of steatosis (grade 1, n=3; grade 2, n=1). The degrees of fibrosis, as assessed by the pathologist ranged up to a score of 4 and DIA based percentage area of fibrosis ranged up to 34%.

In all cases, the ADC values of liver derived without fat suppression were slightly less than those derived using fat suppression. The average ADC values of the liver specimens without fat suppression was  $0.72 \times 10^{-3} \text{ mm}^2/\text{s}$  and the average derived with fat suppression was  $0.75 \times 10^{-3} \text{ mm}^2/\text{s}$ . The mean difference between ADC values derived with and without fat suppression was  $0.03 \pm 0.01 \times 10^{-3} \text{ mm}^2/\text{s}$ . Based on scatterplot comparisons, poor correlation ( $R < 0.25$ ) was seen between difference in ADC values of murine liver with and without fat suppression and both subjective degrees of fibrosis determined by the pathologist and digital image analysis derived values of percentage areas of fibrosis. Similar to the murine liver, in all cases, the ADC values of PBS derived without fat suppression were slightly less than those derived using fat suppression. The average ADC value of the PBS without fat suppression was  $2.19 \times 10^{-3} \text{ mm}^2/\text{s}$  and the average derived with fat suppression was  $2.23 \times 10^{-3} \text{ mm}^2/\text{s}$ . The mean difference between ADC values derived with and without fat suppression was  $0.03 \pm 0.02 \times 10^{-3} \text{ mm}^2/\text{s}$ .

**Conclusion:** In a mouse model of fibrosis, in the absence of steatosis, slight differences between ADC values derived with and without fat suppression were measured. No significant correlation between the differences in ADC values and degrees of liver fibrosis were seen and, thus, this difference in ADC values does not represent a confounding effect in deriving ADC values of the liver in the presence of variable degrees of fibrosis. The lack of more significant effects of fat suppression on ADC and the absence of correlation with fibrosis has implications for deriving hepatic ADC in the clinic in which fat suppression is routinely employed.

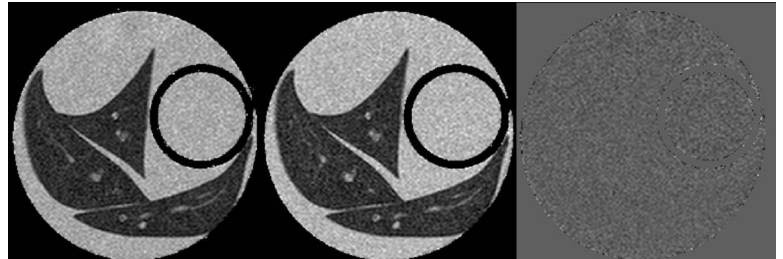

Figure 1. Parametric ADC maps from diffusion weighted images without (left) and with (middle) fat suppression. Internal reference vial containing PBS shown adjacent to the liver specimen. Subtraction image is shown to the right.

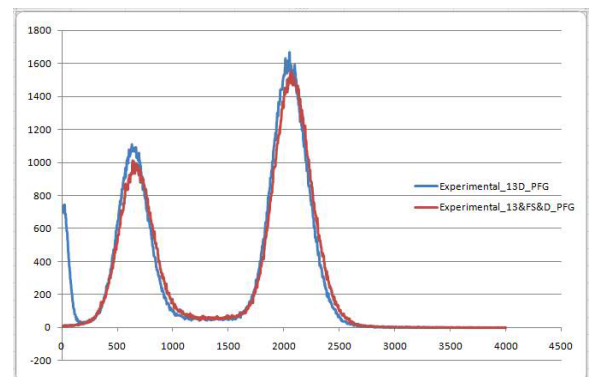


Figure 2. Histograms of parametric ADC maps generated with (red) and without (blue) fat suppression. PBS (rightward peak) and liver (middle peak) demonstrate small rightward shift of the ADC values of the fat suppressed sample. The leftward peak is an olive oil component of the reference vial which, as expected, is suppressed with fat suppression.