

Reproducibility of apparent diffusion coefficients in the normal uterus during the menstrual cycle at 3T MR imaging

A. Tsukabe¹, I. Imaoka¹, T. Araki¹, K. Nishimatsu¹, M. Okada¹, S. Kumano¹, K. Ishii¹, R. Ashikaga¹, M. V. Causeren², and T. Murakami¹

¹Radiology, Kinki University School of Medicine, Osaka-sayama, Osaka, Japan, ²Philips Healthcare, Asia Pacific

Purpose

Change in apparent diffusion coefficients (ADCs) in the normal uterus during a menstrual cycle among reproductive women was reported at 1.5T. In this study, we measured the ADCs of the uterine zonal structures during two menstrual cycles to investigate the reproducibility among intra- and inter-individual variation during the menstrual cycle.

Materials and Methods

The study protocol was approved by our institution's ethics committee and written informed consent was obtained from participants. Five healthy female volunteers of reproductive age (age range, 24-47 years; mean, 38.4 years) participated in the study. MR scans were performed once a week for sequential two menstrual cycles.

MR images were obtained with a 3T unit (Achieva, Philips Healthcare) using a cardiac 32ch coil. Single shot EPI-diffusion weighted images (b=1000, and 0) with SPAIR and SSGR (slice selective gradient reversal) for fat suppression, and ADC values were calculated. The parameters were: TR/TE=5546/55msec, FOV 350mm, matrix 256×256, 5mm slice thickness with no slice gap, and SENSE reduction factor 3. Axial images were obtained and an oval region of interest (ROI) was placed on each uterine structure (endometrium, myometrium, and junctional zone) and internal obturator muscle.

Results

Both intra- and inter-individual variation of ADCs was larger in the endometrium than in the other structures (table 1). ADC values in endometrium tended to increase from proliferative phase to early secretory phase in all five women, and inter-individual difference was minimum at early secretory phase (figure 1). Figure 2 shows ADC changes of each uterine structure in one volunteer. Similar cyclic changes could be seen between two menstrual cycles intra-individually.

	endometrium	JZ	myometrium	obturator internus
1	0.81-1.54	0.75-0.96	1.15-1.50	1.31-1.56
2	0.90-1.43	0.67-0.96	1.48-1.68	1.40-1.76
3	1.16-1.82	0.89-1.20	1.36-1.46	1.17-1.60
4	0.82-1.46	0.79-1.18	1.17-1.82	1.40-1.59
5	1.10-1.37	0.80-0.99	1.37-1.71	1.36-1.49

Conclusion

We observed changes in ADC values in the normal uterus during menstrual cycle at 3T. The intra-individual reproducibility was seen during menstrual cycle. Though inter-individual ADC values were varied, we suggest that the early secretory phase is suitable for the assessment of ADC, especially in endometrium.

Reference A Kido, et al BJR 83(2010), 524-8

Table1. ADC values ($\times 10^{-3} \text{ mm}^2 \text{ s}^{-1}$)

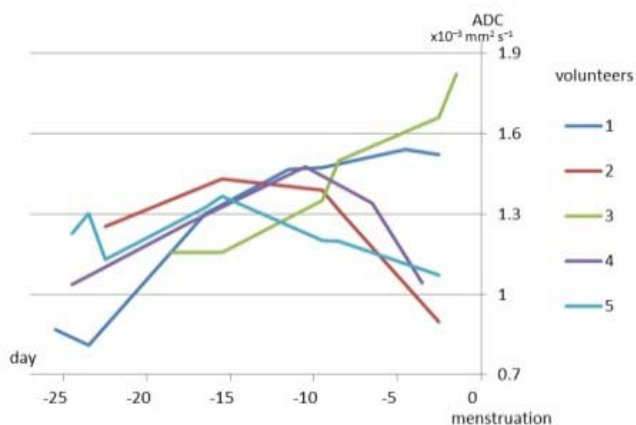


Figure 1. ADCs of endometrium in five women

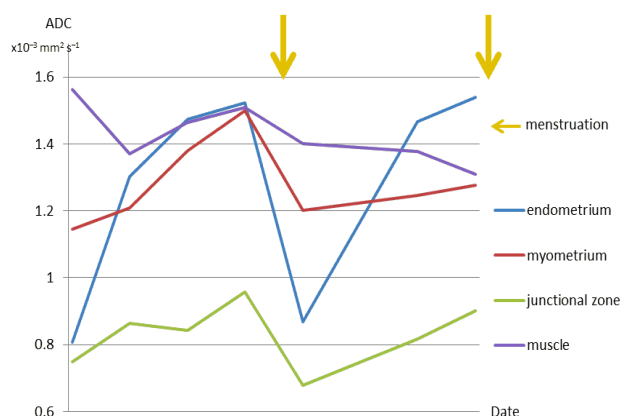


Figure 2. ADCs in one woman