

Quantification of T1 relaxation time of liver and spleen before and after oxygen inhalation in patients with and without liver cirrhosis

K. Kim^{1,2}, M-S. Park², I. Kim³, M-J. Kim², and K. Kim²

¹Radiology, Inje University Ilsan-Paik Hospital, Goyang-si, Gyeonggi-do, Korea, Republic of, ²Radiology, Yonsei University College of Medicine, Seoul, Korea, Republic of, ³Siemens Medical Solution

Introduction: Oxygen affects on MR signals by a paramagnetic property of deoxyhemoglobin and a paramagnetic property of molecular oxygen itself. After inhalation of 100% oxygen, the concentration of dissolved oxygen in arterial blood increases by about five times without significant change in the amount of oxyhemoglobin as shown on the characteristic sigmoid-shaped oxygen-hemoglobin dissociation curve. Previous studies with 1.5-T MRI showed that significant change of the T1 relaxation time after oxygen inhalation in spleen with high arterial blood flow, but no significant change of it in the normal liver. The purpose of this study is to quantify T1 relaxation times of liver and spleen before and after oxygen inhalation in patients with and without liver cirrhosis.

Methods: Approval by the Institutional Review Board and written informed consent from all patients was obtained. 62 non-cirrhotic patients and 106 patients with liver cirrhosis (85 Child-Pugh class A and 21 Child-Pugh class B or C) underwent MR imaging at 3.0 T system (Magnetom Tim Trio; Siemens Medical solution, Erlangen, Germany) before and after 100% oxygen inhalation at the rate of 15 L/min via non-breathing ventilation mask during 3 minutes. T1 maps were acquired using 3D spoiled gradient echo sequences with two different flip angles (2° and 14°) and fixed TR/TE (2.54 ms/0.95 ms). T1 values of liver and spleen were obtained using T1 processing tool (MapIt software, Siemens Medical Solutions, Erlangen, Germany) before and after oxygen inhalation. (Fig 1) Baseline T1 values and $\Delta T1$ ($T1_{pre} - T1_{oxygen}$) was calculated and compared between three groups (control, Child-Pugh class A, Child-Pugh class B/C) using student t-test.

Results: The mean T1 value of liver before oxygen inhalation was higher in non-cirrhotic patients (947.58) than that in cirrhotic (866.06), Child-Pugh A (876.20), and Child-Pugh B/C (825.024) patients with statistical significance ($p = 0.002, 0.007, \text{ and } 0.005$, respectively). The mean $\Delta T1$ value of liver before and after oxygen inhalation was higher in non-cirrhotic patients (52.673) than that in cirrhotic (17.649), Child-Pugh A (20.313), and Child-Pugh B/C (6.867) patients. The baseline T1 value and $\Delta T1$ of spleen were lower in non-cirrhotic patients than those in cirrhotic patients (Child-Pugh A and B/C) without significance. After oxygen inhalation, T1 value of the liver and spleen was decreased in all of the patients.

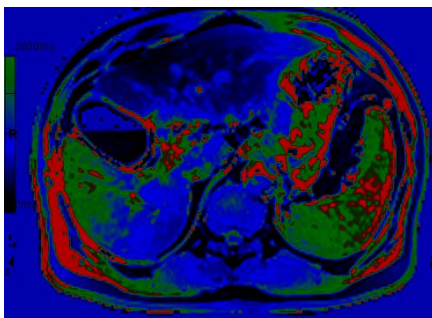


Fig 1. Color coded image of T1 mapping acquired after automatic post-processing in patient with liver cirrhosis (Child-Pugh B)

Discussion and conclusion: Baseline T1 relaxation time of liver and T1 shortening effect of oxygen on liver were significantly different between the patients with and without liver cirrhosis. Quantification of oxygen effects on T1 relaxation time has a potential to be a noninvasive alternative to liver biopsy for the diagnosis of liver cirrhosis.