

# In vivo T2 Measurements of the Right Ventricle Inferior Wall: Comparison with the Left Ventricle

B. Fernandez<sup>1,2</sup>, M. Lohezic<sup>1,2</sup>, L. Hammen<sup>2,3</sup>, M. Beaumont<sup>4,5</sup>, D. Mandry<sup>2,4</sup>, P-A. Vuissoz<sup>2,3</sup>, and J. Felblinger<sup>2,3</sup>

<sup>1</sup>Global Applied Science Laboratory, GE Healthcare, Nancy, France, <sup>2</sup>IADI Lab, Nancy-Université, Nancy, France, <sup>3</sup>U947, INSERM, Nancy, France, <sup>4</sup>CHU de Nancy, Nancy, France, <sup>5</sup>CIT801, INSERM, Nancy, France

## INTRODUCTION:

Many studies have reported *in vivo* measurement of left ventricular (LV) T2 which is consequently well quantified [1-4]. On the contrary, the right ventricular (RV) T2 has not been widely investigated. It has been shown that the RV T2 is significantly longer than the LV T2 [5,6]. However, Buxt *et al.* [7] showed a slightly longer T2 value for the RV but not significantly longer. This lack of references can be explained by the difficulty to depict the thin RV walls using standard double inversion recovery fast spin echo (DIR-FSE) sequence [8]. Recently, RV inferior wall has been shown to be better depicted with DIR-FSE sequence in end-systolic rest thanks to a new adaptive and predictive method [9]. This method aims at adaptively positioning the fast spin echo acquisition during the end-systolic rest while keeping the inversion time required to suppress the blood signal. In the present study, this new method is used to assess T2 on both LV and RV during end-systolic rest. T2 measurements on the LV and RV are then compared together on fourteen volunteers.

## METHODS:

**MR Experiment:** To compare the T2 of the RV inferior wall and the LV, fourteen healthy volunteers (28.7 ± 11 years, weight 70.9 ± 14.3 kg, height 1.72 ± 0.1m; 7 males) underwent a cardiac examination on a 1.5T scanner (HDx, General Electric, Waukesha, WI) using a standard eight-element cardiac coil. This study was approved by the local ethics committee and conducted in compliance with laws on clinical research. Informed consent was obtained for all volunteers. A single short-axis slice placed at mid-LV was acquired during the end-systolic rest period using the adaptive DIR-FSE sequence as reported by Fernandez *et al.* [9]. To measure T2, seven images were acquired with different echo times (TE) ranging from 10 to 70 ms, in step of 10 ms. Other acquisition parameters are presented in table 1.

**Image analysis:** First, the images were manually registered to compensate for motion which may occur between successive breath holds. Then the myocardium was manually segmented. For the LV, the normalized segmentation in six segments for the mid-ventricular plane was used [10]. For the RV, a region-of-interest (ROI) was drawn on the RV inferior wall as depicted on figure 1. Finally, the T2 values were estimated using a mono-exponential model (Eq. (1)) with the Levenberg-Marquardt fitting algorithm provided by Matlab (The MathWorks Inc, Natick, MA).

$$S(TE) = S_0 e^{-TE/T_2} \quad (1)$$

S(TE) represents the ROI mean signal intensity.

**Statistical analysis:** RV T2 was compared to the values estimated on the entire LV myocardium. To investigate for non-uniform spatial distribution, comparison was extended to LV segments adjacent to the RV (i.e. segment 3 and 4 as depicted on figure 1). First, a Kolmogorov-Smirnov test was performed on each dataset to confirm that they are consistent with a normal distribution. Then, a two-sided paired student t-test was used to determine statistical differences between T2 measurements on the RV and those on the LV. The three sets of T2 LV measurements (i.e. on the entire LV, on the segment 3 and on the segment 4) were also compared to each other to ensure that differences were not linked to spatial position. P-values smaller than 0.01 were considered statistically significant.

## RESULTS:

Three volunteers were rejected from the image analysis due to a poor image quality on the RV. The mean T2 for all volunteers of the RV inferior wall was 63.97±5.26 ms. For the LV, T2 was 53.96±3.86 ms on the entire myocardium, 55.96±5.83 ms on the segment number 3 and 52.89±6.58 ms on the segment number 4. The Kolmogorov-Smirnov test demonstrated that all four dataset could be considered as Gaussian distributed (p>0.5). The RV inferior wall T2 was significantly different from the whole LV T2 (p<10<sup>-4</sup>), from the LV segment 3 (p<0.005) and from the LV segment 4 (p<0.0005). No significant differences were found between measurements made on the LV (p>0.02). These results are summarized on figure 2. Fitting regression coefficients R<sup>2</sup>, representing the fitting quality, were in the same range for every measurement. R<sup>2</sup> was 0.96±0.03 for the RV, 0.97±0.04 for the entire LV, 0.096±0.04 for the segment 3 and 0.096±0.03 for the segment 4.

## DISCUSSION AND CONCLUSION:

In this study, the feasibility of measuring the T2 of the RV thanks to an adaptive method [9] has been demonstrated. T2 estimated on the RV inferior wall was significantly longer than T2 of the LV (around 10 ms). This increased of T2 values of the RV has been explained by the water content and hydroxyproline concentration [5]. These results are in concordance with other independent studies [5,6,7]. Moreover, compared to Scholz *et al.* [6] that only uses two TEs, the new adaptive method provides a more robust framework with many TEs to estimate T2 of both RV and LV. Such measurements should also benefit from the use of the axial plane which may enable a better depiction of the RV [8]. Further studies should be conducted on a larger population, including normal and pathological T2 values, to confirm our preliminary conclusions. Since T2 of the fat is longer than the T2 of the myocardium, T2 measurement on the RV could be used to detect or to quantify intramyocardial fatty infiltration in patient with ARVD [11].

**REFERENCES:** [1] Marie *et al.* JACC 37(3):825-831 (2001). [2] Cobb *et al.* JMRI 30:684-689 (2009). [3] He *et al.* JMRI 24:580-585 (2006). [4] Stanis *et al.* MRM 54:507-512 (2005). [5] Scholz *et al.* MRI 7(6):643-648 (1989). [6] Scholz *et al.* JMRI 1(5):513-520 (1991). [7] Buxt *et al.* MRI 11(3):375-383 (1993). [8] Berkowitz *et al.* MRM 61:307-314 (2009). [9] Fernandez *et al.* MRM in press (2010). [10] Cerqueira *et al.* Circulation 105:539-542 (2002). [11] Castillo *et al.* Radiology 232:38-48 (2004).

TE	10 to 70ms
TR	1 or 2RR
TI	500ms
Matrix size	256x256
FOV	36cm
BW	125kHz
Slice thickness	6mm
ETL	16

Table 1: Acquisition parameters depending on heart rate

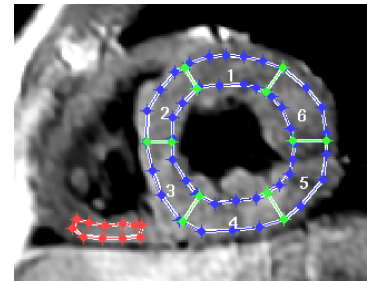


Figure 1: the normalized segmentation of the LV (blue and green) and a ROI drawn on the RV inferior wall (red).

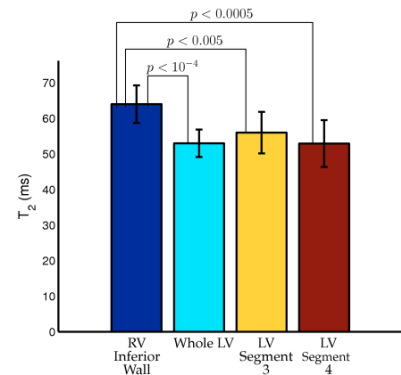


Figure 2: mean and standard deviation of the RV inferior wall, the whole LV, the LV segment 3 and 4.