

Correlation of Phase values with CT Hounsfield and R2* values in calcified Neurocysticercosis

B. Roy¹, S. Verma², R. Awasthi¹, R. K. Rathore², R. Venkatesan³, S. Yoganathan⁴, K. Maria Das⁴, K. N. Prasad⁵, and R. K. Gupta¹

¹Radiodiagnosis, Sanjay Gandhi Post Graduate Institute of Medical Sciences, Lucknow, India, Lucknow, Uttar Pradesh, India, ²Mathematics & Statistics, Indian Institute of Technology, Kanpur, Kanpur, Uttar Pradesh, India, ³Wipro-GE Healthcare, Bangalore, Karnataka, India, ⁴Radiotherapy, Sanjay Gandhi Post Graduate Institute of Medical Sciences, Lucknow, India, Lucknow, Uttar Pradesh, India, ⁵Microbiology, Sanjay Gandhi Post Graduate Institute of Medical Sciences, Lucknow, India, Lucknow, Uttar Pradesh, India

Introduction

CT is considered as a gold standard for demonstration of the calcified lesions. On CT, a Hounsfield unit (HU) of 80 or more is considered as confirmatory evidence of calcification. Susceptibility weighted imaging has been widely used in evaluating presence of iron and/or calcium. Phase images contain information about local susceptibility changes between tissues, which is useful in measuring iron content and other substances that changes the local field¹. Neurocysticercosis (NCC) is a parasite of the brain, present with single or multiple cysts in symptomatic and asymptomatic subjects especially in endemic regions across the world. It has been shown that a calcified lesion may show a positive or both negative and positive phases on MRI which appear as a uniformly high signal density lesion on CT. The presence of a diamagnetic substance (calcium) results in a positive phase while paramagnetic substance (predominant iron concentration in the scolex) causes a negative phase². We quantified the phase in these lesions with an aim to correlate these values with CT-HU as well as R2* values by co-registering CT and T2star weighted angiography (SWAN) imaging.

Material and Methods: A total of fifty two calcified cysts from 35 patients with a diagnosis of NCC on the basis of approved guidelines³, were included in the study.

Data acquisition: All the patients underwent conventional MRI on a 3T MR scanner (Signa Hdx, General electric, Milwaukee, USA), using a 12 channel head coil after the approval from the institutional ethics committee. Conventional MRI was performed in the axial plane with a field of view (FOV) = 240 × 240 mm², slice thickness = 3 mm, interslice gap = 0.0mm. In addition, SWAN sequence with TR/TE/Flip Angle/slice thickness: 47/25/15/2.4mm and acquisition matrix of 320x224 was also performed for the detection of these lesions.

MRI data processing and quantitative analysis Complex data consisting of real and imaginary parts was collected using a multiecho SWAN imaging. The phase calculation removing the susceptibility artifacts was done according to Haacke et al¹ using a 64 × 64 low pass filter to remove the low spatial frequency component of background field. A linear fit was used to calculate the R2* from the same multi echo SWAN data. The MRI and CT data sets were registered using mutual information^{4,5} and MLE⁶ was used to segment the lesion.

Statistical analysis Spearman's correlation was performed to see the correlation between quantitative phase and CT-HU & R2* values. Mann-Whitney U test was used to look for differences between CT-HU and R2* values obtained from corresponding positive and negative phase regions.

Results

In a volume of lesion, both positive and negative phases were noted (Fig.1). From the regions with positive & negative phase, R2* and CT values were calculated separately. The median values of CT-HU and R2* from the regions with positive phase & negative phase were found to be 142.10 (range: 41.89-491.75) and 0.0685 (range: 0.02-0.11) & 137.30 (range: 30.83-458.88) and 0.069 (range: 0.00-0.11) respectively. There was a significant correlation of positive phase values with corresponding CT-HU values. The positive phase value also showed a significant correlation with the R2* values. In addition, there was a significant correlation of R2* values and CT-HU values with negative phase values (Fig.2). There was no significant difference of CT-HU and R2* values between positive and negative phase regions.

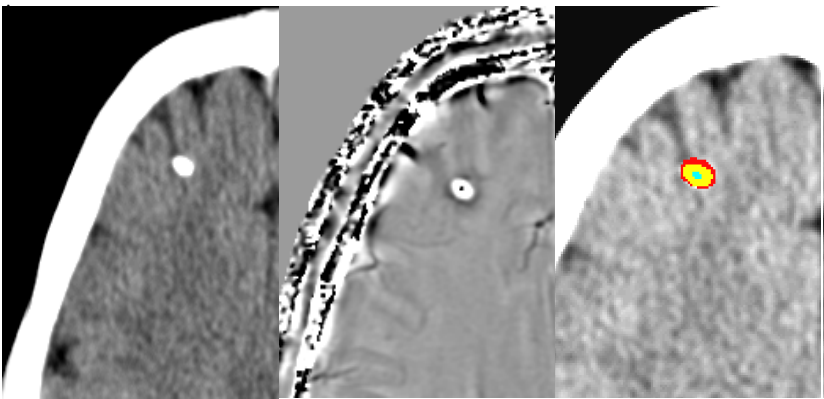


Fig.1 Showing CT, Filtered phase image showing both positive & negative phase, and segmented calcified cyst overlaid on CT image, cyan representing scolex, yellow-body of the cyst and red- showing brain tissue surrounding the cyst

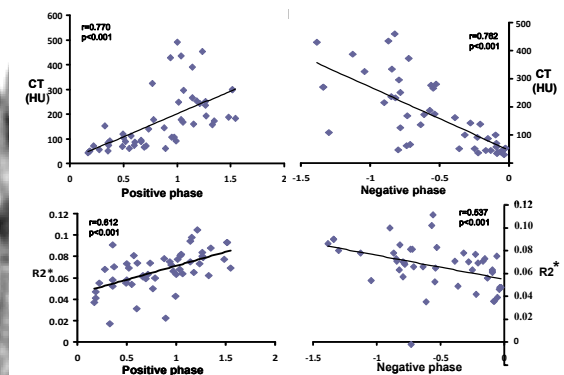


Fig.2 Scatter plots showing significant correlation of CT Hounsfield values and R2* with positive and negative phase values (in radians)

Discussion: Our results suggest that quantitative phase imaging separates diamagnetic from paramagnetic minerals from a CT calcified lesion. The insignificant difference of CT-HU obtained from regions of corresponding positive and negative phase values confirm the earlier observations the CT density does not differentiate between these two types' of materials. Quantification of minerals from the scolices have show high concentration of iron besides calcium suggesting mixed composition of the minerals in this structure². The results of R2* values were similar to CT, suggesting that the mixture of these minerals influences the R2* and probably contributes to its inability to separate these materials from the CT calcified lesions. Significant correlation of the phase values with CT HU and R2* suggest that phase MRI imaging may be used to detect calcified lesions. In addition phase imaging appears to have advantage over CT in differentiating these minerals which help in demonstration of scolex in the calcified blob which is considered pathognomonic of the disease and cannot be shown by any other in vivo technique.

References: 1.Haacke et al. 2009 *AJNR*;30:19-30, 2.Chawla et al. 2002 *Clinical Radiology*;57: 826-834, 3.Del Brutto OH. 2005 *Semin Neurol*;25:243-51, 4.Awasthi et al. 2010 *JCAT*;34:82-8. 5. Verma, et al. 2008 *ESMRMB, 25th Annual Meeting, Valencia*, 6. Rathore et al. April 2001 *Proc. 9th Scientific Meeting of ISMRM at Glasgow*.