

Parallel RF excitation for diffusion-weighted whole body MR imaging with background body signal suppression at 3.0 Tesla.

G. M. Kukuk¹, M. Kaschner¹, F. Träber¹, D. Skowasch², J. Gieseke^{1,3}, H. H. Schild¹, W. A. Willinek¹, and P. Mürtz¹

¹Department of Radiology, University of Bonn, Bonn, NRW, Germany, ²Department of Pneumology, University of Bonn, Bonn, Germany, ³Philips Healthcare, Best, Netherlands

Introduction: Diffusion-weighted whole-body imaging with background body signal suppression (DWIBS) at 1.5 T has been introduced in 2004 by Takahara et al. [1]. DWIBS uses short TI inversion recovery (STIR) in order to reach good fat suppression over a large imaging area and facilitates whole body examination during free breathing in an acceptable acquisition time. DWIBS offers 3D visualization of lymph nodes and malignant lesions with impeded diffusion throughout the entire body. Up to now, DWIBS at 1.5 T is clinically applied for tumor and metastasis detection, lymph node imaging, and monitoring cancer therapy. The implementation of DWIBS at higher magnetic field strength is more challenging due to more pronounced susceptibility artefacts, less uniform fat suppression, and longer acquisition times [2,3]. Recently, it has been shown that the use of dual-source parallel RF excitation with patient-adaptive B1 shimming (TX) results in improved image quality and reduced acquisition times in clinical routine body MRI at 3.0 T [4]. The aim of this study was to evaluate the effect of TX on DWIBS with respect to acquisition time, signal homogeneity, fat suppression, and apparent diffusion coefficient (ADC).

Methods: Institutional review board approval and informed consent from all patients was obtained. 40 consecutive patients (26 male, 14 female, mean age 59±15 years) with known or suspected malignant disease were examined on a clinical 3.0T whole-body MRI system (Philips Achieva 3.0T TX) equipped with TX as described in [4]. Prior to each acquisition a B1-map was acquired for calibration of the independent RF sources. Patients underwent a routine MR sequence protocol including contrast media injection. A diffusion-weighted single-shot spin-echo echo-planar imaging sequence (70 transversal slices with 3.5 mm thickness, FOV = 400 mm × 339 mm, matrix 132 × 112, EPI-factor = 59, half-fourier-factor = 0.638, b = 0 with NSA = 2, b_{max} = 1000 s/mm² with NSA = 3, motion probing gradients in three orthogonal directions, parallel acceleration (SENSE) factor 2) with STIR fat suppression at TI = 260 ms [2] and slice-selective gradient reversal (SSGR) [3] was acquired during free breathing. Isotropic diffusion-weighted (DW) images were calculated and DWIBS images were reconstructed as grey-scale inverted MIP reconstructions of the isotropic DW images. To keep the acquisition time within an acceptable range only one body region per patient was examined with and without TX (2:56 and 3:37 min, respectively). The following body regions were examined: neck (n=5), chest (n=8), abdomen (n=6), and pelvis (n=21). DW and DWIBS images were visually judged by two readers in consensus. Image homogeneity, fat suppression, and lesion/lymph node conspicuity were rated on a four point scale as "improved", "equal", "worse" or "ambiguous" with the standard RF excitation protocol as reference. ADC values of lesions (n=21), urine bladder (n=20), and skeletal muscle (n=57) were measured for DWIBS acquired with and without TX. All lesions were correlated and confirmed by contrast-enhanced MRI and/or PET-CT. Statistical significance (p<0.05) was tested with the non-parametric Wilcoxon signed-rank test in case of visual scoring results and with Student's t-test in case of quantitative ADC analysis.

Results: By using TX, image homogeneity was "improved" in 24/40 (60%) of the examinations (neck 3/5 (60%), chest 6/8 (75%), abdomen 5/6 (83%), pelvis 10/21 (48%)). Fat suppression was "improved" in 17/40 (43%) of the patients. The improvements in image homogeneity and fat suppression were statistically significant (both p<0.001). In none of the cases, a degradation of image homogeneity or fat suppression or an "ambiguous" result was found for the use of TX. Lesion/lymph node conspicuity was "improved" in 3 patients with ascites or liquid containing lesions (see Figure) and "equal" in all other cases. The resulting ADC values (in units of 10⁻⁶ mm²/s) for DWIBS with and without TX were 1094±336 vs. 1056±312 for lesions, 1530±124 vs. 1520±140 for the muscles and 2959±235 vs. 3017±247 for urinary bladder. The measured differences (all data included) were not significant (p=0.823). The scan time was reduced by 33% for the protocol with TX.

Conclusion: The use of parallel RF excitation in DWIBS at 3.0 T reduced acquisition time by 33% and significantly improved image quality with respect to signal homogeneity, fat suppression, and dielectric shading without influencing ADC values.

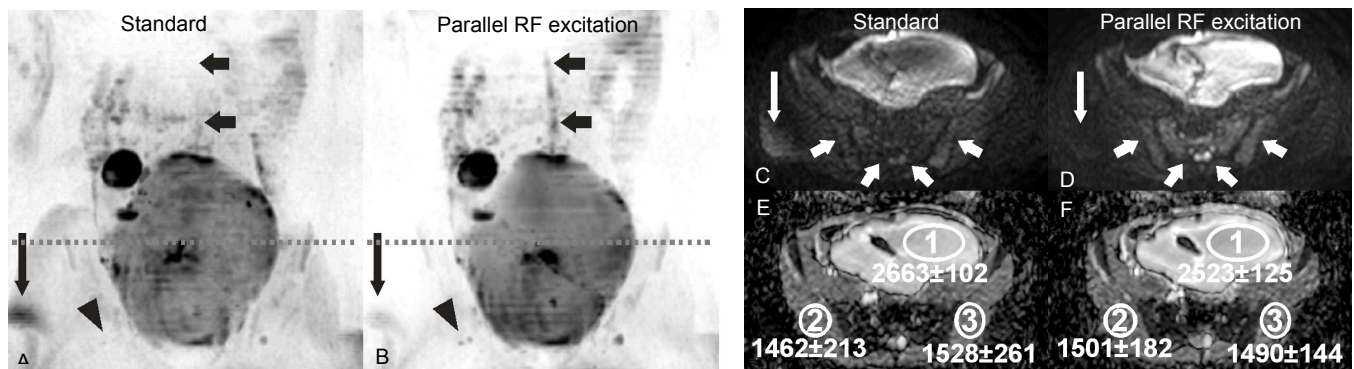


Figure: DWIBS images (A,B), transverse isotropic DW images (C,D), and ADC maps (E,F) of a 18 year old patient with a germ cell tumor. Images acquired with TX (B, D) were rated as "improved" with respect to signal homogeneity in anterior-posterior direction (resulted e.g. in better delineation of spinal cord, short black arrows) and fat suppression (large white and black arrows). The lesion/lymph node conspicuity was "improved" (e.g. iliac lymph nodes, arrowheads) due to less dielectric shading by using TX. ADC values of gluteal muscles (E,F) agreed within 3% for both RF excitation techniques.

References: [1] Takahara T, Imai Y, Yamashita T, et al. Radiat Med 2004;22:275-282. [2] Mürtz P, Krautmacher C, Träber F, et al. Eur Radiol 2007;17:3031-3037. [3] Horie T, Ogino T, Muro I, et al. Proc of the 17th ISMRM, Honolulu, Hawaii, USA, p 4034. [4] Willinek WA, Gieseke J, Kukuk GM, et al., Radiology 2010;256:966-975.