

Differences in thalamic activity and in the temporal pattern of Bold signal between neonates born at term and preterm: a fMRI study during passive auditory stimulation.

E. Scola¹, S. Pontesilli¹, R. Scotti¹, V. Blasi¹, R. Longaretti¹, P. Scifo^{1,2}, S. Cirillo¹, A. Iadanza¹, A. Poloniato³, G. Barera³, G. Scotti¹, and C. Baldoli¹
¹Neuroradiology Department - CERMAC, San Raffaele Scientific Institute, Milano, Italy, ²Department of Nuclear Medicine, San Raffaele Scientific Institute,
³Neonatology and Neonatological Intensive Care Unit, San Raffaele Hospital, Milan, Italy

Objective: Aim of this study was to assess, with functional magnetic resonance imaging (fMRI), in non-sedated preterm and healthy term neonates, the maturation of cortical areas activated during linguistic passive stimulation and to evaluate the correlation between fMRI activation and brain maturation. These aspects have been investigated in order to highlight the differences between the population of preterm and healthy term neonates.

Background: The primary auditory cortex (AC) represents an area of increased vulnerability in the preterm brain, because temporal lobe undergoes a critical period of intensive synaptogenesis during the third trimester of gestation, a time when many preterm children are born [1]. Several MRI studies evaluating the cerebral structural sequelae of preterm birth have consistently reported alterations in the regions subserving language [2]. Previous fMRI studies of auditory tasks at school age in children and preadolescents born prematurely suggest that they develop auxiliary or alternative systems for the neural processing of common language tasks [3]. Early investigation of cerebral functions may provide important prognostic informations in children born prematurely.

Methods: Twenty preterm infants, 25-33 weeks of gestational age (GA) underwent a longitudinal MRI study on a 3 Tesla Scanner (Intera, Philips Medical System, Best, The Netherlands). T2 and T1 weighted images were obtained in order to rule out brain lesions. A fMRI study (Echo planar gradient-echo sequence; repetition time 2200 ms; echo time 40 ms; flip angle 90°; 18 slices; voxel size 2.8x2.8x4mm³; SENSE reduction factor 2.00) during a passive language listening task was performed. FMRI consisted in a block design paradigm, including 3 sessions of 70 scans each, alternating 5 volumes of activation (a passive listening task of a fairytale condition) and 5 volumes of rest condition. All preterm infants were studied three times: at time 1 within 34th week of equivalent age (EA), at time 2 at 40 weeks of EA and at time 3 at 44 weeks of EA. As control group 16 healthy term neonates were studied only once at birth with the same MR protocol. Inclusion criteria were: absence of haemorrhagic or ischemic brain lesions on morphological MRI, stable clinical condition with no need of respiratory and nutritional support. FMRI data were analyzed using spm5 software (<http://www.fil.ion.ucl.ac.uk/spm>) according to the General Linear Model. To reduce deformation due to different brain shape in preterm newborns at time 1 compared to the other subjects, the images were normalized to two independent ad hoc created templates based on anatomical images, one for preterm infants at time 1 and one for all the other subjects. The analyses of blood oxygenation level dependent (BOLD) signal comprised the haemodynamic response function (HRF) model; temporal derivative (TD) was added to. Six movement parameters were added as regressors. Both BOLD signal increase and decrease were considered. For each scan of each subject, t-maps were calculated. Second-level random effect analysis (1 sample t-test) with t-maps was then performed for a group based analysis.

Results: In preterm subjects the second level group-based random effect analysis (1-sample t-test) with the HRF model, performed for time 1, time 2 and time 3 data, showed a cortical activation in superior temporal cortex in the left side at time 1 and bilaterally at time 2 and at time 3 ($p < 0.001$, 5 voxels). In healthy term subjects, besides a bilateral superior temporal cortex, it was observed also a bilateral activation in the area of medial geniculate body and auditory thalamus ($p < 0.001$, 5 voxels). Moreover, it was observed that the detection of superior temporal cortical activation in preterm newborns at time 1 and 2 needed the addition of TD; on the contrary the TD addition in BOLD analyses was not necessary for the preterm infants group at time 3 and for the healthy term subjects group.

Conclusion: The longitudinal aspect of this study allowed the observation of auditory cortex functional modifications during the early stages of brain development. The BOLD signal was detected in preterm newborns since the 29th week of EA. Changes in superior temporal cortex functional activation were studied in preterm subjects from time 1 to time 3 and a peculiar temporal pattern of BOLD signal was observed in preterm infants groups at time 1 (within 34th week of EA) and at time 2 (at 40 weeks of EA). This may be related to the immaturity of neuro-vascular coupling, previously observed in newborns [4]. Moreover, results demonstrated a bilateral posterior thalamic activation in healthy term neonates not present in neonates born preterm. This result may be related to a different development of transient thalamo-cortical connections between neonates born prematurely and neonates born at term [4]. FMRI may provide insights on impact of brain injury on developing neural system, adding functional informations to morphological MR scan.

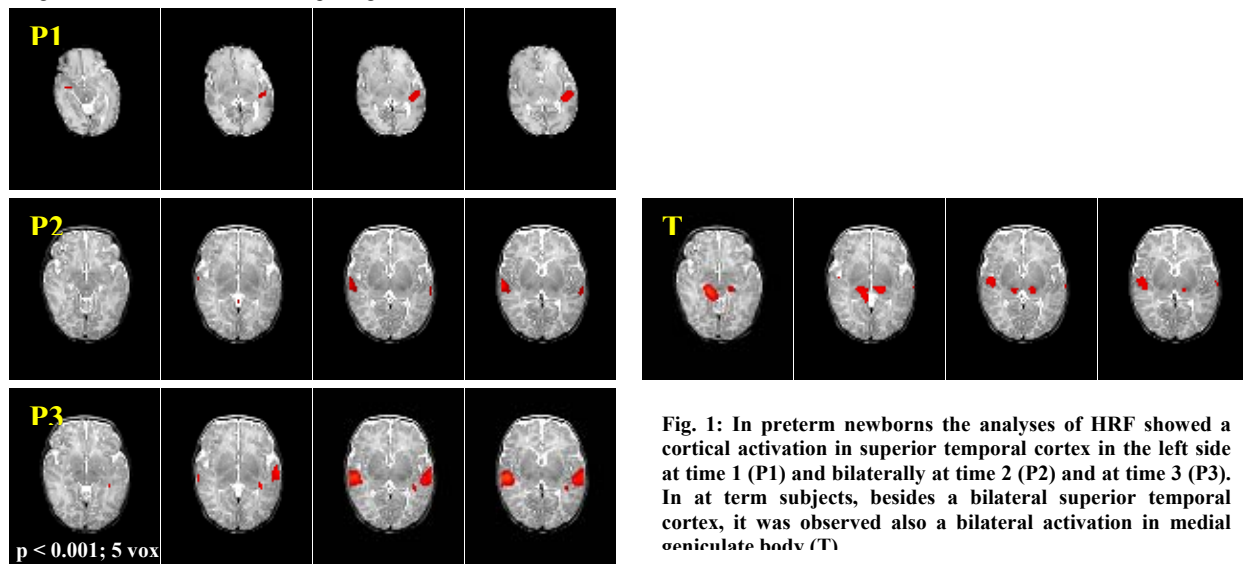


Fig. 1: In preterm newborns the analyses of HRF showed a cortical activation in superior temporal cortex in the left side at time 1 (P1) and bilaterally at time 2 (P2) and at time 3 (P3). In at term subjects, besides a bilateral superior temporal cortex, it was observed also a bilateral activation in medial geniculate body (T)

1 - Armstrong E, Schleicher A, Omran H, Curtis M, Zilles K. The ontogeny of human gyrification. *Cereb Cortex* 1995; 5:56-63.

2 - Nosarti C, Giouroukou E, Healy E, Rifkin L, Walshe M, Reichenberg A, Chitnis X, Williams SC, Murray RM. Grey and white matter distribution in very preterm adolescents mediates neurodevelopmental outcome. *Brain* 2008; 131:205-217.

3- Ment LR, Peterson BS, Vohr B, Allan W, Schneider KC, Lacadie C, Katz KH, Maller-Kesselman J, Pugh K, Duncan CC, Makuch RW, Constable RT. Cortical recruitment patterns in children born prematurely compared with control subjects during a passive listening functional magnetic resonance imaging task. *J Pediatr* 2006; 149:490-498.

4- Kluckow M. Low systemic blood flow and pathophysiology of the preterm transitional circulation. *Early Hum Dev* 2005; 81:429-437.