

ADC-FLAIR Mismatch Excluding Enhancement (AFMEE), a Potential Biomarker of Tumor Invasion

P. S. LaViolette¹, A. D. Cohen¹, S. D. Rand², W. Mueller³, and K. M. Schmainda²

¹Biophysics, Medical College of Wisconsin, Milwaukee, WI, United States, ²Radiology, Medical College of Wisconsin, Milwaukee, WI, United States, ³Neurosurgery, Medical College of Wisconsin, Milwaukee, WI, United States

INTRODUCTION The detection of invading brain tumor cells, beyond the traditional contrast-enhancing regions, continues to be a challenge for the treatment of brain tumors. While areas of FLAIR enhancement represent vasogenic edema, some regions are thought to contain invading brain tumor cells. There currently exists no non-invasive way to identify these tumor infiltrating subregions using images collected at one time point. Specifically, though decreases in apparent diffusion coefficient (ADC) have been shown to correlate with an increase in tumor cellularity¹⁻⁵, this measurement requires the collection of diffusion images at two separate time points. Alternatively, we have observed that regions of heightened FLAIR do not necessarily correspond to regions of heightened ADC expected from increased extracellular fluid. In fact in some cases, heightened FLAIR corresponds to a lower ADC value, what we refer to here as an ADC-FLAIR mismatch, i.e. low ADC within high FLAIR signal. We hypothesize that these regions are potentially indicative of brain tumor invasion. In this study we

analyze invasive and non-invasive brain tumor phenotypes measuring ADC-FLAIR mismatch with a comparison across tumor type.

METHODS Twenty patients with brain tumors were evaluated for this study. Thirteen of them had pathologically confirmed malignant invasive glioblastomas, while 7 had benign noninvasive meningiomas. Patients underwent routine clinical imaging prior to surgery, which included contrast-enhanced T1, FLAIR, and diffusion weighted imaging (DWI). DWI was used to calculate ADC. Each image then went through a series of segmentations. All segmentations were processed using FAST (FMRIB tool library). T1+C images were segmented to determine regions of enhancement. These voxels were then excluded from subsequent analysis under the assumption that known viable tumor exists there. FLAIR images were also segmented to determine regions of heightened signal. ADC maps were then

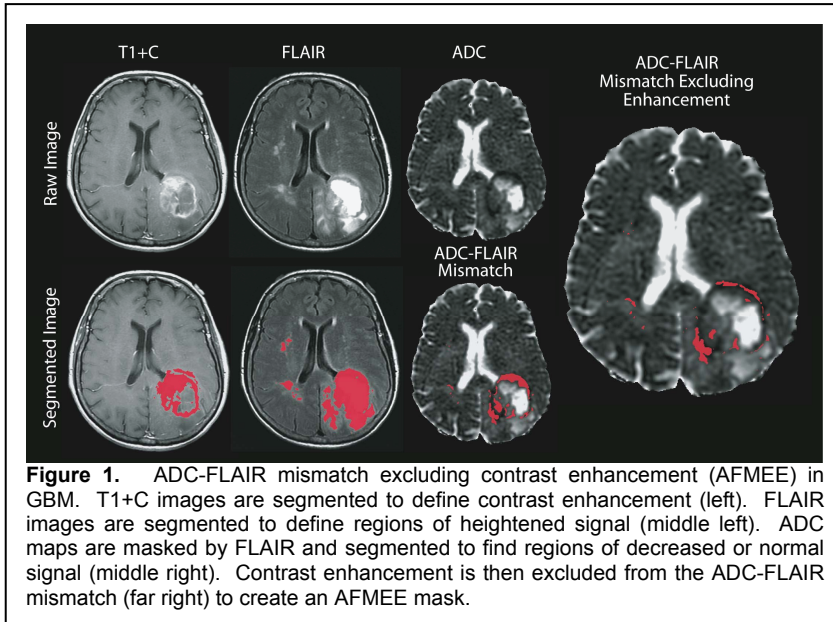


Figure 1. ADC-FLAIR mismatch excluding contrast enhancement (AFMEE) in GBM. T1+C images are segmented to define contrast enhancement (left). FLAIR images are segmented to define regions of heightened signal (middle left). ADC maps are masked by FLAIR and segmented to find regions of decreased or normal signal (middle right). Contrast enhancement is then excluded from the ADC-FLAIR mismatch (far right) to create an AFMEE mask.

masked with the enhancing FLAIR ROIs, and then further segmented to determine regions of decreased or normal ADC, where normal ADC was defined as having been segmented similarly to contra-lateral normal-appearing white matter. Finally areas of contrast enhancement were excluded resulting in the identification of the ADC/FLAIR mismatch regions excluding enhancement (AFMEE). The percent volume of AFMEE was determined as a percentage of the entire FLAIR-enhancing area, with enhancement excluded. These values were then compared across tumor type with a two-sample t-test.

RESULTS Figure 1 shows a representative GBM patient, and a demonstration of the segmentation algorithm used. The resulting AFMEE is shown on the far right overlaid on ADC. The ratio of AFMEE to FLAIR enhancement was significantly different when comparing meningiomas and glioblastomas, $p < 0.001$ (Figure 2).

DISCUSSION We show that AFMEE is a potential biomarker for brain tumor invasion that can be obtained at a single imaging time point. The feasibility of this approach is supported by the clear difference in AFMEE volumes observed between invasive (GBM) and non-invasive (meningioma) brain tumors. Studies are underway to validate this approach with tissue samples obtained at surgery and registered with the pre-surgical images.

Acknowledgements: NIH/NCI RO1 CA082500, Advancing a Healthier Wisconsin.

REFERENCES

1. Sugahara T, et al. *J Magn Reson Imaging*. Jan 1999;9(1):53-60.
2. Hayashida Y, et al. *AJNR* Aug 2006;27(7):1419-1425.
3. Ellingson BM, et al. *J Magn Reson Imaging*. Mar;31(3):538-548.
4. Hamstra DA, et al. *Proc Natl Acad Sci U S A*. Nov 15 2005;102(46):16759-16764.
5. Moffat BA, et al. *Proc Natl Acad Sci U S A*. Apr 12 2005;102(15):5524-5529.

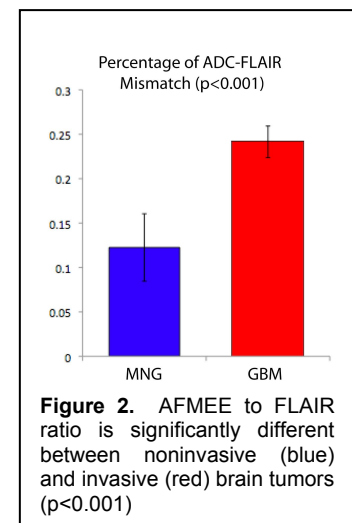


Figure 2. AFMEE to FLAIR ratio is significantly different between noninvasive (blue) and invasive (red) brain tumors ($p < 0.001$)