

T₁, T₂ and ADC as imaging biomarkers for tumor treatment response in brain tumors

P. Brynolfsson¹, T. Asklund², A. Garpebring¹, and T. Nyholm²

¹Umeå University, Umeå, Sweden, ²Department of Oncology, Norrland University Hospital, Umeå, Sweden

Introduction

Malignant gliomas are the most common type of brain tumors in adults with a median survival of 1 – 3 years. [1] Today, evaluation of tumor treatment response is based on estimating change in tumor size one to two months after completed radiochemotherapy. The delayed feedback prevents (a) modifying or desisting ineffective treatment strategies which could reduce patient discomfort, or (b) adapting treatment plans on an individual level, potentially prolonging life expectancy.

Aim

The aim of this study was to identify imaging biomarkers for early treatment response using quantitative MRI based on T₁, T₂ and ADC.

Patients and methods

13 patients with a total of 18 tumors were included in the study. 8 patients underwent radiotherapy concomitant with temozolomide as a first line treatment and 5 patients received bevacizumab in combination with cytostatic drugs as a second line treatment. Each patient was followed in the treatment course by four consecutive quantitative MRI examinations; baseline, 1 week, 2 weeks and 6 weeks from treatment start. An inversion recovery sequence with 6 inversion times in the range 100 – 2000 ms was used to measure T₁, a spin echo sequence with 8 echoes in the range 15 – 120 ms was used to measure T₂ and a twice refocused diffusion sequence using 6 b-values in the range of 0 – 1000 s/mm² was used to measure ADC. All measurements were performed using a Siemens Espree 1.5T scanner with a conventional 4 channel head coil. All images for each patient were registered using rigid registration with a mutual information metric implemented through ITK. Parameter maps were generated using nonlinear regression methods which also constructed standard error maps reflecting the uncertainty of each parameter voxel value estimate. Each tumor was delineated on a diagnostic T₁ weighted contrast enhanced image and the mean value and standard error of each parameter T₁, T₂ and ADC was calculated based on the tumor VOIs. Voxels with a standard error > 20% were excluded due to unreliable parameter estimates. Conventional clinical follow-up was performed at three months after the end of treatment by clinical radiologists who were blinded to the results of the study. Two sample t-tests were performed to test if regressing and progressing tumors could be distinguished at different time points.

Results

The clinical evaluation of treatment response showed that 10 tumors in 4 patients showed a progression and 8 tumors in 7 patients showed a regression or stable disease. Two weeks after treatment start there was a significant decrease in the average values of T₁ and ADC for progressive tumors, p = 0.05. A ROC curve showing the ability to predict outcome from ADC data is shown in fig. 1. The area under the curve, AUC, was 0.90 ± 0.10 and significantly larger than 0.5, p < 0.001. The optimal cut-off point was 0.95 relative to the baseline measurements. Six weeks after treatment start all parameters showed a significant decrease for progressive tumors, p = 0.05, and a significant increase for tumors in regression or stable disease, p = 0.05, which is shown for T₁ and ADC in fig. 2. A two-sample t-test showed that the two groups (progressive disease vs. stable/regression) could be distinguished with p < 0.001 for all three parameters.

Conclusion and discussion

This study indicates that the relative change in the average values of T₁ and ADC correlates to treatment response of glioma patients 2 weeks after treatment start. At 6 weeks after treatment T₁, T₂ and ADC showed a clear separation depending on tumor response. There seemed to be a difference between first line and second line treatment; however more data is needed to investigate that relationship further.

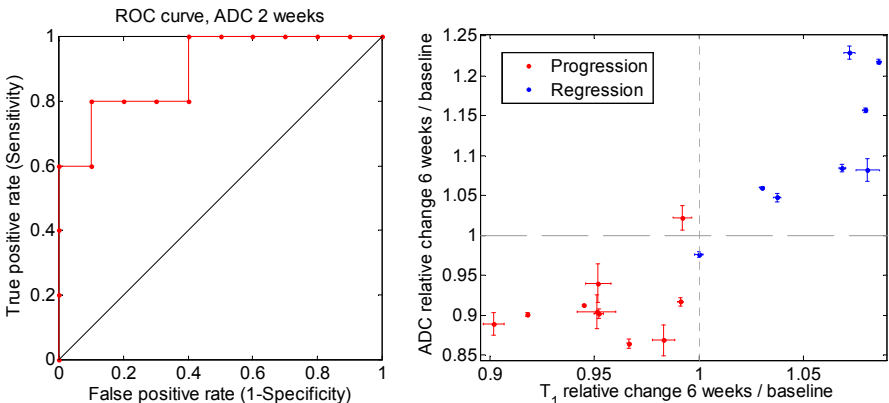


Fig. 1. A ROC curve showing the ability of ADC to separate progression from regression.

Fig. 2. An increase in T₁ and ADC relative to baseline 6 w after treatment start correlates with radiologic regression three months after end of treatment.

References

1) Stupp, R., et al., Radiotherapy plus concomitant and adjuvant temozolomide for glioblastoma. N Engl J Med, 2005. 352(10): p. 987-96.