

Evaluation of changes in gliomas structural features after chemotherapy using DTI-based Functional Diffusion Maps (fDMs): a preliminary study with intraoperative correlation.

A. Castellano¹, M. Donatini^{2,3}, L. Bello⁴, G. De Nunzio^{2,3}, M. Riva⁴, G. Pastore², G. Casaceli⁴, R. Rudà⁵, R. Soffietti⁵, G. Scotti¹, and A. Falini¹

¹Neuroradiology Unit and CERMAT, Scientific Institute and University Vita-Salute San Raffaele, Milan, Italy, ²Department of Materials Science, University of Salento, Lecce, Italy, ³INFN (National Institute of Nuclear Physics), Lecce, Italy, ⁴Neurosurgery, Department of Neurological Sciences, University of Milano, Milan, Italy, ⁵Neuro-oncology, Department of Neuroscience and Oncology, University of Torino, Turin, Italy

Introduction and objectives

The characterization of tumoral tissue obtained by splitting the diffusion tensor into its isotropic (p) and anisotropic (q) components allows to reveal tumoral and peritumoral abnormalities in gliomas that are not apparent on conventional MR imaging and to detect the presence of microscopic tumor cells infiltration in white matter around the edge of the gross tumor, as confirmed by image guided biopsies [1]. The evaluation of this microscopic infiltration could also give better insights into the assessment of response to chemotherapy, as changes in pattern of water diffusion after successful or failed treatment could occur prior to alteration in size, thus reflecting a dynamic reorganization of the heterogeneous tumor structure during chemotherapy.

Recently, changes in diffusion and perfusion metrics during treatment have been evaluated by parametric response maps, that allow a voxel-by-voxel comparison of measures over time with respect to a baseline map. This voxel-wise approach, when referred to the evaluation of ADC changes, is termed the functional diffusion maps (fDMs) [2,3]. In this study, we aim to evaluate diffusion tensor decomposition-derived metrics in a functional manner, by applying fDMs analysis to isotropic (p) and anisotropic (q) maps during neuroradiological follow-up of patients undergoing to dose-dense temozolomide chemotherapy before second-look surgery; changes in diffusion parameters within tumor tissue are correlated both with neurophysiological data from intraoperative subcortical mapping and histopathological findings from specimens obtained from image-guided tumor biopsies.

Methods

Eight patients with low-grade gliomas were studied. MR studies were acquired at the baseline and after five cycles of temozolomide (TMZ) at a dose of 150 mg/m²/die 1 week on/1 week off, without any concomitant treatment that can modify diffusion parameters (i.e. steroids). Inclusion criteria for dose-dense TMZ were as follows: 1) patients with suspected low grade glioma, who are unresectable or candidate to a partial resection only, and have undergone a diagnostic biopsy; 2) patients who had a partial resection at first surgery and have progressed clinically (increasing seizures) and/or radiologically. 3T MR-DTI consisted of a single-shot EPI sequence (TR/TE 8986/80 ms) with parallel imaging (SENSE factor, R = 2.5). 32 diffusion gradient directions ($b=1000$ s/mm²) and one image set without diffusion-weighting were obtained. The sequence was repeated two consecutive times and data were averaged off-line to increase signal-to-noise ratio. 3D-FLAIR sequences, T2-weighted FSE and pre and post-gadolinium volumetric T1-weighted FFE conventional images were acquired for morphological characterization of the lesions and volumetric assessment. The evaluation of response was primarily based on conventional FLAIR images, using modified Mac Donald's criteria that categorized patient's response as partial (PR), stable disease (SD) or progressive disease (PD) [6].

Diffusion maps were obtained using an in-house software implemented in MATLAB to produce p and q maps (the isotropic and anisotropic components of the diffusion tensor). Both manual and automated segmentation of pathological areas based on 3D Texture Analysis, as previously described [7] was performed on each map; then, after a step of realignment of DTI studies acquired after five cycles of chemotherapy to pretreatment scans using a mutual information algorithm [8], a comparison between segmented tumor regions of interest (ROIs) with a voxel-by-voxel approach allowed to verify the modification of tumor tissue features after chemotherapy. Each voxel was classified into three categories based on the change in diffusion parameters from the pretreatment scan to last time point. For definition of p and q thresholds used for fDMs, the 95% confidence intervals for changes in voxel-wise diffusion parameters applied on whole brain normal-appearing white matter (NAWM), gray matter (NAGM), and cerebrospinal fluid (CSF) was used. Red voxels represented areas within the tumor where isotropy or anisotropy increased, blue voxels represented decreased values of p and q . Diffusion maps were loaded into neuronavigational system as described in [9], to correlate modification of diffusion parameters with neurophysiological findings from intraoperative subcortical mapping and to obtain, at surgery, different specimens from different areas of the maps for histological study.

Results

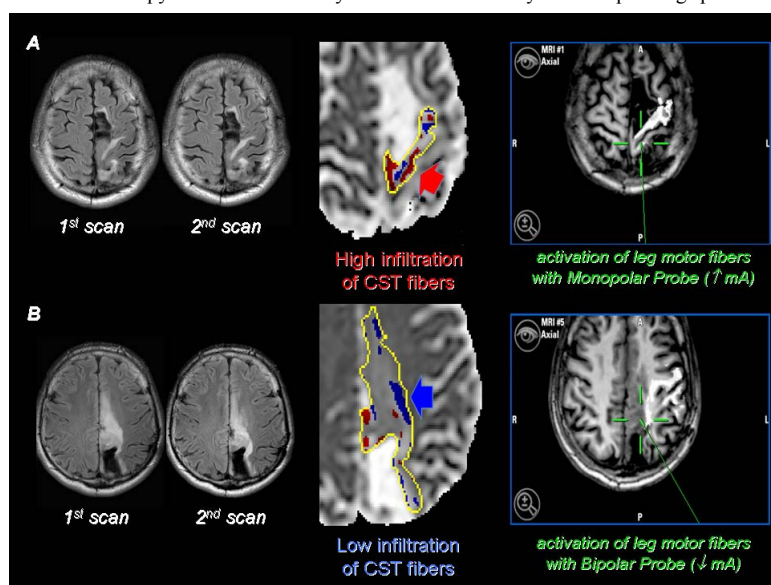
Seven patients had stable disease at conventional imaging, and one had progressive disease. In all patients modifications of isotropy and anisotropy values (p and q) were seen after chemotherapy; particularly, in patients with stable disease, diffusion changes on p maps were detected in peripheral tumor areas, along the infiltrative margins of the tumor, in which significant changes in p without modification in q were observed, in accordance with [1]. These changes were displayed as red or blue areas on p and q maps, and correlate with neurophysiological findings from intraoperative mapping (Fig. 1). Regions of increased isotropy over time are characterized by a high infiltration of fibers, requiring the use of monopolar probe for stimulation; regions of decreased isotropy are characterized by a reduced infiltration of fibers, and the activation of fibers was achieved by the use of bipolar probe.

All image-guided biopsies obtained along tumor margins depicted by DTI segmentations showed neoplastic infiltration. Tumor infiltration areas corresponded to the areas depicted on p maps: an increase of cell density was observed in samples corresponding to areas of increased isotropy over time, whereas regions of decreased isotropy are characterized by a reduced cell density in corresponding specimens.

Discussion and Conclusions

The proposed DTI-based method, when benchmarked against morphologic imaging criteria, seems to provide an indication of response to treatment prior to alteration in size; structural changes showed by DTI-based fDMs suggest the hypothesis of a "shrinkage" of the tumor in response to chemotherapy, well characterized by diffusion tensor decomposition maps both at the level of tumor core and margins of infiltration, and confirmed by intraoperative findings. The preliminary results of this study indicate a suitable method capable of providing important informations about the heterogeneous structural changes of gliomas in response to treatment in a preoperative setting, that could be proposed as a part of an integrated approach, beside other MR advanced techniques like MR spectroscopy and perfusion, to evaluate response to therapy and possibly to suggest the timing for surgery.

◀ Fig.1. A case of low grade oligodendroglioma with SD at conventional imaging: red areas on fDMs p maps corresponded to regions of high infiltration (A) and blue areas to low infiltration of fibers (B), as confirmed by intraoperative mapping: images from the neuronavigational system (right) show the corresponding sites of stimulation (green marks) evoking motor responses from fibers of corticospinal tract (tractography reconstructions of CST in white, superimposed on T1w images).



[1] Price SJ et al. AJNR 27, 1969-74 (2006). [2] Moffat BA et al. Proc Natl Acad Sci USA 102, 5524-5529 (2005). [3] Hamstra DA et al. J Clin Oncol 26, 3387-3394 (2008). [4] Wick A et al. J Clin Oncol 25, 3357-61 (2007). [5] Duffau H et al. J Neurooncol 80, 171-6 (2006). [6] Macdonald DR et al. J Clin Oncol 8, 1277-1280 (1990). [7] De Nunzio G et al. Proc. Intl. Soc. Mag. Reson. Med. 18: 5105 (2010). [8] Meyer CR et al., Med Image Anal 1, 195-206 (1997). [9] Bello L et al. Neuroimage 39:369-82 (2008).