

Patterns of white matter tract damage in behavioural variant of frontotemporal dementia and primary progressive aphasia: a DT MRI study.

E. Scola¹, F. Agosta², E. Canu², L. Sarro², A. Marcone³, C. Cerami³, G. Magnani⁴, F. Caso⁴, S. F. Cappa^{3,5}, M. Filippi², and A. Falini^{1,6}

¹Neuroradiology - CERMAC, San Raffaele Scientific Institute, Milan, Italy, ²Neuroimaging Research Unit, Scientific Institute and University San Raffaele Hospital, Milan, Italy, ³San Raffaele Turro Hospital, Department of Clinical Neurosciences, Milan, Italy, ⁴Department of Neurology, Institute of Experimental Neurology, Division of Neuroscience, Scientific Institute and University San Raffaele Hospital, Milan, Italy, ⁵Vita Salute University and Department of Clinical Neurosciences, San Raffaele Scientific Institute, Milan, Italy, ⁶Vita Salute University, San Raffaele Scientific Institute, Milan, Italy

Objectives. To assess the patterns of white matter (WM) tract damage in behavioural variant frontotemporal dementia (bvFTD) and primary progressive aphasia (PPA).

Background. Behavioural variant frontotemporal dementia (bvFTD) and primary progressive aphasia (PPA) are the two major clinical presentations of frontotemporal lobar degeneration (FTLD) which is the third most common cause of cortical dementia [1]. Three common forms of PPA are recognized: non-fluent, semantic, and logopenic [2]. Along with a well characterized grey matter (GM) pathology, WM changed have been shown to occur in bvFTD and PPA patients [3-7]. A few studies investigated in vivo the extent of WM integrity in these patients, and how such changes are related to GM atrophy.

Methods. Thirteen bvFTD patients, 20 PPA patients and 32 healthy controls were studied. The PPA patients group included 9 non-fluent, 7 semantic, and 4 logopenic patients. The Clinical Dementia Rating (CDR) (sum of boxes) was 3.9 ± 2.3 for bvFTD, 4.5 ± 2.9 for PPA (respectively 3.2 ± 1.3 for non fluent, 4.9 ± 3.0 for semantic and 3.3 ± 2.6 for logopenic). 3D T1-weighted and diffusion tensor (DT) magnetic resonance imaging (MRI) scans were obtained using a 3.0 Tesla Scanner (Intera, Philips Medical System, Best, The Netherlands). DTI data were acquired using a single-shot echo planar imaging sequence (repetition time/echo time 8986/80 ms) with parallel imaging (SENSE factor, R = 2.5). Thirty-two diffusion gradient directions ($b = 1000 \text{ s/mm}^2$) and one image set without diffusion weighting were obtained. A field of view (FOV) measuring $240 \times 240 \text{ mm}^2$ and a data matrix of 96×96 were used, leading to isotropic voxel dimensions ($2.5 \times 2.5 \times 2.5 \text{ mm}^3$). The data were interpolated in-plane to a matrix of 256×256 leading to voxel size of $0.94 \times 0.94 \times 2.5 \text{ mm}^3$. Acquisition coverage extended from medulla oblongata to the brain vertex (56 slices, no gap). The sequence was repeated twice consecutively and data were averaged off-line to increase signal-to-noise ratio. A 3D T1-weighted (magnetization-prepared rapid acquisition gradient-echo, MP-RAGE; repetition time/echo time 25/4.6 ms, flip angle = 30° , FOV = measuring $230 \times 182 \text{ mm}^2$, 220 axial slices and no gap, voxel size of $0.9 \times 0.9 \times 0.8 \text{ mm}^3$) was also acquired. T2 and FLAIR axial images were obtained to identify any white matter hyperintense area in all subjects and to rule out other potential causes of dementia. WM damage was investigated globally in a voxel-by-voxel analysis as well as in specific fibre tracts. DT images were processed with FSL 4 (<http://www.fmrib.ox.ac.uk/fsl/>). Then, the statistical analyses was performed using the 1.2 version of Tract-Based Spatial Statistics (TBSS), as implemented in FSL. GM atrophy was estimated the T1 3D T1-weighted images with Statistical Parametric Mapping (SPM8, <http://www.fil.ion.ucl.ac.uk/spm/software/spm8/>) and the DARTEL registration method.

Results. BvFTD patients showed the most widespread pattern of WM damage; the most significant alterations were found in the anterior corpus callosum (aCC), and in the cingulum, uncinate, and inferior fronto-occipital fasciculi, bilaterally. Among PPA patients, the non-fluent group had the most extensive pattern of WM damage, with a most significant involvement of aCC, and left superior longitudinal (SLF), uncinate, and cingulum. In semantic patients, the most significant damage involved the temporal WM tracts, with a left predominance. In logopenic patients, DT MRI abnormalities involved the left fronto-parietal SLF and the CC only at a more "liberal" statistical threshold. In bvFTD the GM damage involved most significantly the frontal, temporal lobe and the head of caudate nucleus bilaterally. Semantic patients showed a significant pattern of atrophy in the left anterior temporal lobe. In non-fluent patients the GM damage was depicted in the left anterior insula, in the left temporal lobe and left temporo-parietal area; in logopenic patients in the left superior temporal and in left parietal lobe. In each group, the distinct regional distribution of WM damage extended beyond the topography of GM loss.

Conclusions. DT MRI demonstrated specific patterns of WM damage in bvFTD and PPA patients. Although WM abnormalities mirrored the patterns of GM atrophy, diffusivity changes were also identified in more posterior brain regions, which may be atrophied later in the course of the disease.

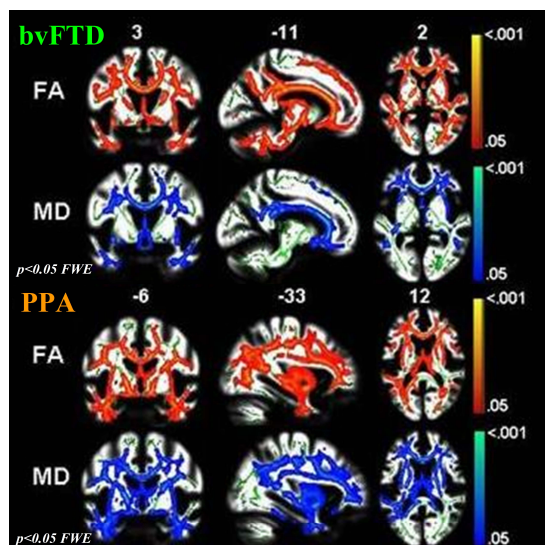


Fig 1: pattern of WM tracts damage in bvFTD and PPA patients.

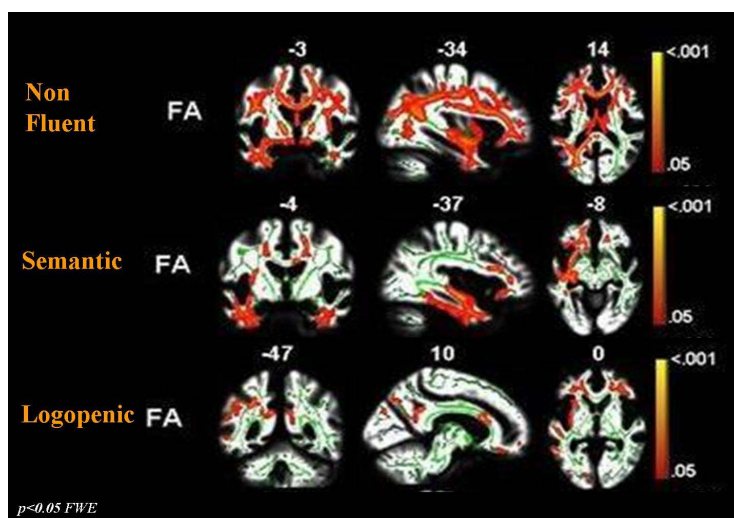


Fig 2: pattern of WM tracts damage in the three forms of PPA patients.

1. Neary D, Snowden JS, Gustafson L, et al. Frontotemporal lobar degeneration: a consensus on clinical diagnostic criteria. *Neurology* 1998;51:1546–1554.
2. Gorno-Tempini M, et al. Cognition and anatomy in three variants of primary progressive aphasia. *Ann. Neurol.* 55, 335-346 (2004)
3. Agosta F, Henry RG, Migliaccio R, et al. Language networks in semantic dementia. *Brain* 2010;133(pt 1):286–299.
4. Borroni B, Brambati SM, Agosti C, et al. Evidence of white matter changes on diffusion tensor imaging in frontotemporal dementia. *Arch Neurol* 2007;64:246–251.
5. Matsuo K, Mizuno T, Yamada K, et al. Cerebral white matter damage in frontotemporal dementia assessed by diffusion tensor tractography. *Neuroradiology* 2008;50:605–611.
6. Yoshiura T, Mihara F, Koga H, et al. Cerebral white matter degeneration in frontotemporal dementia detected by diffusion-weighted magnetic resonance imaging. *Acad Radiol* 2006;13:1373–1378.
7. Zhang Y, Schuff N, Du AT, et al. White matter damage in frontotemporal dementia and Alzheimer's disease measured by diffusion MRI. *Brain* 2009;132:2579–2592.