

Changes in iron concentration of the basal ganglia in Huntington's Disease using magnetic field correlation

M. J. Versluis^{1,2}, E. M. Dumas³, S. J. van den Bogaard³, A. G. Webb^{1,2}, M. A. van Buchem¹, E. P. 't Hart³, M. J. van Osch^{1,2}, J. van der Grond¹, and R. A. Roos³

¹Radiology, Leiden University Medical Center, Leiden, Netherlands, ²C.J. Gorter Center for high field MRI, Leiden University Medical Center, Leiden, Netherlands,

³Neurology, Leiden University Medical Center, Leiden, Netherlands

Introduction: It has been suggested that increased iron levels in subcortical structures is one of the causal factors of the symptoms of Huntington's Disease (HD) [1]. Magnetic field correlation (MFC) is an imaging technique sensitive to magnetic field inhomogeneities (MFIs) resulting from iron accumulations [2]. Unlike relaxation-based methods MFC is not sensitive to changes in water concentration due, for example, to demyelination, and is therefore very suited for investigating and quantifying the iron depositions in neurodegenerative diseases such as HD.

Methods: 27 HD patients (mean age: 49 yrs), 21 premanifest gene carriers (mean age: 45 yrs) and 25 healthy controls (mean age: 50 yrs), from the Leiden site of the TRACK-HD study, underwent 3T MRI (Philips Healthcare, Best, The Netherlands) using an 8 channel receive coil.

Sequence details: An asymmetric spin echo (ASE) sequence was implemented. The position of the refocusing pulse was shifted towards the excitation RF pulse by 0, 2.3, 6.9, 11.5 and 13.8 ms, these values were chosen to have the water and fat signals in phase. The RF shifts result in varying sensitivity to MFIs and based on the different shifts the quantitative MFC maps were calculated [2]. The following scan parameters were used: TR / TE / FA = 1005 ms / 38 ms / 90° with a voxel size of 2 x 2 x 4 mm³ and 18 slices positioned through the basal ganglia. Scan duration was 8 minutes. A T₁-weighted sequence was included for tissue segmentation.

Post-processing: Macroscopic MFIs, resulting mainly from gross anatomy structures (tissue interfaces) were separated from the microscopic contribution (e.g. iron levels) using a field map [3]. Deep grey matter structure segmentation of T₁-weighted scans was performed with FIRST (FSL, Oxford), followed by automated registration of the T₁-scans and structure segmentations with the MFC maps. Voxel wise MFC values were derived and averaged MFC values per nucleus were calculated.

Statistics: Average MFC values were compared in each deep grey matter structure between groups whilst controlling for age.

Results: The MFC values in the caudate nucleus (p=0.03) and putamen (p=0.003) of HD patients were significantly higher than in controls. The MFC in the nucleus lentiformis (pallidum + putamen) was also higher in HD compared to controls (p=0.002). No significant differences were found between premanifest gene carriers and controls. The highest MFC values were found in the pallidum and putamen (figure 2). These values correspond well with known high levels of iron in these nuclei [4].

Conclusion: We have demonstrated that patients with HD have higher MFC values in the caudate nucleus and nucleus lentiformis. These differences are likely to be caused by an increase in iron concentration, and not by changes in water content. Because the MFC method is insensitive to T₂ and T₂* changes that can be caused by e.g. changes in water concentration, it provides a better measure to assess MFIs than other relaxation based methods. In addition the possibility to remove the macroscopic component from the microscopic inhomogeneities results in MFC maps that more clearly represent underlying changes in iron levels. Therefore MFC imaging is well suited to measure iron accumulation in vivo. In summary we conclude that iron accumulation is prominent in the caudate nucleus and nucleus lentiformis in manifest HD patients.

References: 1. Bartzokis et al., Arch. Neurol. 56:569 (1999); 2. Jensen et al. MRM 55:1350 (2006); 3. Jensen et al. MRM 61:481 (2009) 4. Hallgren et al. J Neurochem 3:41 (1958)

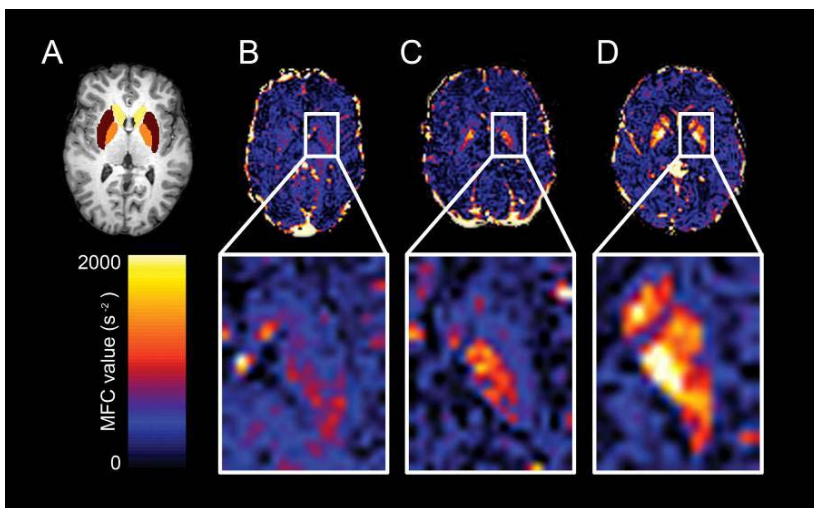


Figure 1: T₁-weighted image and calculated MFC maps.

T₁-weighted image (a), showing segmentation of caudate nucleus (yellow), putamen (brown) and globus pallidus (orange). The corresponding MFC maps for a healthy control (b), premanifest gene carrier (c) and early manifest HD patient (d). High MFC values are found in the subcortical grey matter structures, known to correspond with high iron concentrations

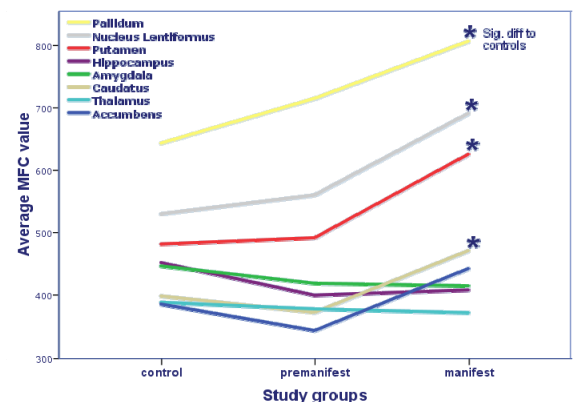


Figure 2 : Average MFC values in all examined nuclei.

Significant changes in MFC value were found in the globus pallidus, putamen, the nucleus lentiformis and the caudate nucleus. * signifies significantly (p < 0.05, corrected for multiple comparisons) different from controls