

Perfusion changes in patients after cardiac surgery: evidence from an n-back working memory task.

T. B. Harshbarger¹, J. Browndyke², A. W. Song¹, and J. Mathews²

¹BIAC, Duke University, Durham, NC, United States, ²ADRC, Duke University, Durham, NC, United States

Introduction: Patients undergoing cardiac surgery often present with postoperative cognitive decline as assessed by cognitive testing. Research evidence indicates that this decline is present in 36% of patients six weeks post-surgery and persists in 42% of patients up to five years after surgery⁽¹⁾. While these changes have been well-characterized by cognitive testing batteries, direct studies of brain function by imaging are lacking. As such, the exact mechanism and form of this cognitive impairment is unknown. As part of an ongoing longitudinal study, we examined potential brain perfusion changes during the completion of a cognitive task (an n-back memory task) in patients before cardiac surgery and in a follow-up six weeks post-surgery. The n-back memory task is known to involve a large network of brain regions in normal subjects⁽²⁾. The aim of this report was to determine if changes in perfusion occur within this network in patients who have undergone cardiac surgery.

Methods: A total of five subjects, who successfully completed imaging sessions pre-surgery and six weeks post-surgery, were included in this study. All imaging was performed on a GE 3T Excite system. As part of the imaging session, arterial spin labeling was used to measure perfusion with a modified FAIR sequence using QUIPSS II saturation pulses⁽³⁾ (TI1/TI2 600/1600 ms, TR/TE 3000/20 ms, 4x4x5 mm resolution, 37 tag-control pairs). During the perfusion scan, subjects performed an n-back task continuously. Quantitative maps of perfusion were determined for each session. Data were spatially normalized using SPM5. High resolution T1 weighted images were acquired in the same sessions, and used to create gray matter masks. The cerebral blood flow (CBF) within the masked region was measured and averaged. The pre- and post-surgery CBF maps were examined with a paired t-test in SPM5 to determine changes in perfusion. In addition, individual maps of the absolute difference in perfusion were created and these differences were converted to t-scores. In this way, we could look at overall CBF changes, as well as potential local changes.

Results and Discussion: For global measures of CBF, no significant change in perfusion levels was found for any subject. However, localized differences did reach significance. For the paired t-test, a significant postoperative positive change was found in the superior frontal gyrus (Fig. 1), an area known to correspond with increased demands in an n-back task⁽⁴⁻⁷⁾. No significant decreases in perfusion levels were found. Within individual maps, an area of the anterior cingulate cortex known to be active in the n-back task commonly displayed a significant increase in perfusion post-surgery, as can be seen in two representative subjects in Fig 2. Other areas showing changes in perfusion were diffuse and not as consistent across subjects, and this activation only partially overlapped between subjects. These results indicate that consistent differences in perfusion levels are found across subjects. A general overall decline in perfusion was not seen. The observed changes were not due to differences in task performance, as subjects were practiced before imaging so as to reach near 100% accuracy with little variation. This means differences in perfusion were due to other factors, such as increased cognitive demands to maintain performance levels. It is possible that a decrease in reserve capacity leads to changes in the hemodynamic response globally and causes the general cognitive decline. Concurrent imaging of blood volume (CBV) would allow us to determine if the decline is related to vascular changes or neuronal damage.

Conclusions: We have shown that perfusion changes occur in localized areas after cardiac surgery, although there is no overall change in perfusion level. Future studies measuring CBF, CBV, and BOLD would allow for better determination of the nature of cognitive decline in these patients.

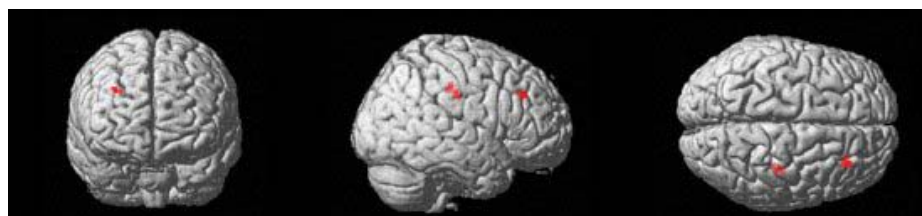


Fig 1: Perfusion increases after surgery compared to pre-surgery levels during the n-back task in the superior frontal gyrus.

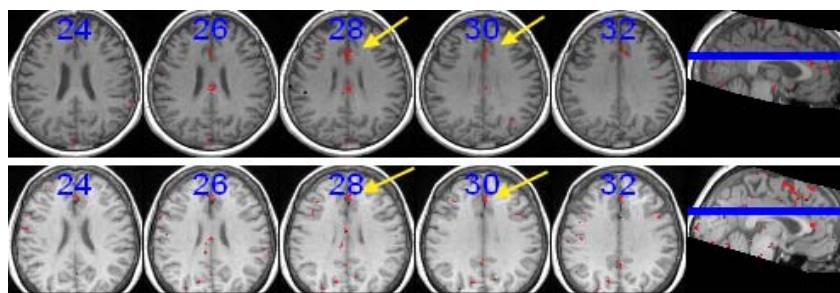


Figure 2: Two representative subjects showing consistent increases in perfusion after surgery within the anterior cingulate cortex.

References: 1) Newman et al., N Engl J med 2001 344(6); 2) Owen et al., Hum Brain Mapp 2005 25(1); 3) Wong et al., Magn Reson Med 1998 39(5); 4) Carlson et al., Cereb Cortex 1998 8(8); 5) Christoff and Gabrieli, Psychobiology 2000 28(2); 6) Pochon et al., PNAS 2002 99(8); 7) Wishart et al., Am J Psychiatry 2006 163

Acknowledgements: We would like to thank Dr. Thomas Liu for supplying the ASL sequence and analysis software.