

White Matter Cerebral Blood Flow Measurement in Mild Cognitive Impairment and Alzheimer's Disease Using an Arterial Spin Labeling Method

Y. Jung¹, T. T. Liu¹, and C. E. Wierenga^{2,3}

¹Radiology, University of California, San Diego, La Jolla, CA, United States, ²Psychiatry, University of California, San Diego, La Jolla, CA, United States, ³Veterans Affairs San Diego Healthcare System, San Diego, CA, United States

INTRODUCTION

Alzheimer's disease (AD) is a neurodegenerative brain condition with no effective treatment. Traditionally viewed as a disease of gray matter (GM), neuroimaging techniques have revealed decreased GM volume, metabolism and blood flow with disease progression. However, increasing evidence indicates that white matter (WM) alteration precedes medial temporal lobe (MTL) atrophy [1], and diffusion tensor imaging has shown abnormalities in WM in mild cognitive impairment (MCI; thought to be a transitional stage between normal aging and dementia) and AD groups [2]. Reflecting the close relationship between blood perfusion and metabolism in the brain, alterations in blood perfusion may be a precursor to structural damage. Therefore, the study of changes in WM cerebral blood flow (CBF) may provide important information for early diagnosis and monitoring of disease progression in MCI and AD. Previously a study using single-photon emission computed tomography (SPECT) showed declines of WM CBF in the posterior region of the brain in AD [3]. Arterial spin labeling (ASL) MRI is a completely non-invasive method for measuring blood perfusion quantitatively, but it is known to have physiological and physical limitations with regards to the measurement of WM perfusion [4]. Here we investigated the potential of ASL to detect differences in WM CBF between groups of older adults with intact cognition, MCI, and AD.

METHOD

We performed ASL scans on 9 subjects from each of three groups: normal cognitively intact control (NC), MCI, and AD. AD diagnosis was made according to NINCDS-ADRDA criteria and MCI diagnosis was made according to Jak, et al. [5]. Groups did not differ on age, sex distribution, APOE distribution, and education and the demographic variables and raw scores on the Dementia Rating Scale (DRS) are shown in Table I.

The experiment was executed on a 3T Signa HDx scanner with an 8-channel head coil (GE Healthcare, Waukesha, WI). A FAIR ASL [6] scan was performed with QUIPSS II post-inversion saturation pulses [7] and scan parameters were 22cm FOV, 20 slices (5mm thick, 1mm gap), T1/TI2 = 600ms/1600ms, 2.5sec TR, 20 tag/control pairs, 160 reps, and 6:40 min. scan time. 4-shot spiral acquisition (TE = 3ms) was used to reduce signal dropout due to susceptibility effects and image blurring, which can induce large partial volume effects. A high resolution anatomical scan was obtained to define the white matter and gray matter masks. Thresholds for the partial volume fraction were set to 0.95 for white matter and 0.8 for gray matter.

All images were transformed into Talairach space and the Talairach Daemon [8] was used to delineate white matter regions of interest (ROIs) for 6 major fissures and lobes in each hemisphere (see Fig. 1). The ROIs were multiplied by the white or gray matter mask to restrict the tissue types within the ROIs. To account for partial volume effects, only CBF values in the median 50% were included in the calculation. Mean WM CBF was extracted for each ROI per subject, and average WM CBF in each ROI was compared between groups using t-tests.

RESULTS AND DISCUSSION

Fig. 2 shows the mean WM CBF for the three clinical groups in all 12 ROIs. The AD group showed reductions of WM CBF in right parietal and right occipital regions. Compared to the MCI group, the AD group showed significant hypoperfusion in multiple WM regions (as well as whole brain WM and GM) with the most significant decrease observed in the right occipital region.

Our work shows that ASL has potential utility to indicate abnormalities of blood perfusion in WM in MCI and AD. The results are consistent with the findings from the SPECT study [3], which showed hypoperfusion in the posterior regions of the brain in the AD group.

Whereas a DTI study showed reductions of FA in posterior regions in both MCI and AD [2], our study shows hyperperfusion in MCI compared to control (not statistically significant). This might be explained by the notion of compensation, which suggests perfusion may increase in response to encroaching neural pathology [9].

Even though we observe significant differences of WM CBF, the methods we used have limitations for voxel-based analysis because of low SNR, widespread transit times in WM, partial volume effects, and short T1 in WM. Of greatest concern is the sensitivity to transit delays which may exaggerate hypoperfusion in the presence of vascular abnormalities that induce a long transit delay.

REFERENCES

1. Gold et al., NeuroImage, v52: p1487, 2010.
2. Medina et al., Neu Aging, v27: p663, 2006.
3. Siennicki-Lantz et al., Dement Geriatr Cogn Disord, v9: p29, 1998.
4. van Gelderen et al., MRM, v59: p788, 2008.
5. Jak et al., Am J Geriatr Psychiatry, v17: p368-75, 2009
6. Kim et al., MRM, v37: 425-435, 1997.
7. Wong et al., MRM, v39: 702-708, 1998.
8. Lancaster et al., HBM, v10: p120, 2000.
9. Dai et al., Radiology, v250: p856, 2009.

Table I. Demographic variables of clinical groups

	NC	MCI	AD
Sex (M/F)	4/5	4/5	4/5
Age (yr.)	73.7±7.8	74.2±9.9	74.8±9.3
Education (yr.)	16.3±2.4	15.2±2.3	14.8±2.2
APOE (33/34/44)	4/5/0	4/3/2	4/3/2
DRS	142±2	137±5	126±6

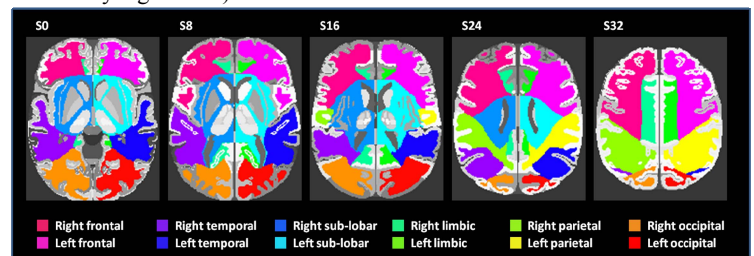


Figure 1. ROIs defined based on the Talairach Daemon [6]. The cerebrum is segmented into 6 principal fissures and lobes in each hemisphere.

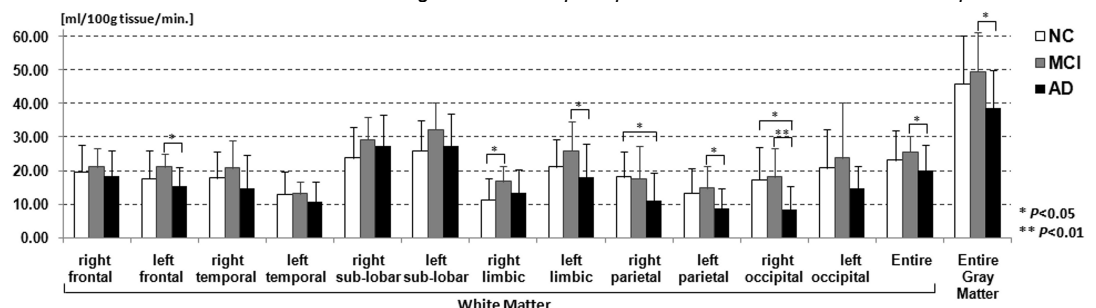


Figure 2. Comparisons of WM CBF in normal control, MCI and AD patients. The bars indicate the mean CBF values and the error bars represent the standard deviation across 9 subjects.