

Quantitative analysis of the substantia nigra in Parkinson's disease implementing 3D modeling at 7.0T MRI

H.-J. Jeong¹, S.-H. Oh¹, J.-M. Kim², D.-H. Kwon¹, S.-Y. Park¹, J. Park¹, Y.-B. Kim¹, J.-G. Chi^{1,3}, C.-W. Park¹, B. Jeon², and Z.-H. Cho¹

¹Neuroscience Research Institute, Gachon University of Medicine and Science, Incheon, Korea, Republic of, ²Department of Neurology, College of Medicine, Seoul National University, Seoul, Korea, Republic of, ³Departments of Pathology, College of Medicine, Seoul National University, Seoul, Korea, Republic of

Introduction

Parkinson's disease (PD) is a neurodegenerative disorder resulting from progressive loss of dopaminergic (DA) neurons in the substantia nigra (SN). Especially the degree of neuronal loss was significantly higher in the nigrosomes and the degree of loss of dopamine-containing neurons in the substantia nigra was related to the duration of the disease.[1] In our previous study, attempts have been made to directly visualize the SN and quantify the differences in shapes and boundaries of SN between PD subjects in comparison to the normal control subjects using two dimensional (2D) T₂*-weighted 7.0T MRI images.[2] However, 2D analysis does not represent entire structure of the SN. Therefore, we have acquired 3D images of the SN to overcome the limits of 2D analysis.

Methods

Nine PD patients [3 men and 6 women; age range, 51-70 years; mean age, 59.77 ± 7.4 years] and nine age-matched normal controls [1 men and 8 women; age range, 52-67 years; mean age, 59.00 ± 4.9 years] were included in this study. 3D MR images were performed on a 7.0T whole body scanner (Magnetom, Siemens). The used specific MR imaging parameters were: TR/TE = 50/25 ms, flip angle = 10°, total acquisition time = 8.23 min, bandwidth = 30 Hz/pixel and matrix size = 504x576, in-plane resolution was 0.35 mm iso-voxel. In addition, we obtained whole brain image using T₁-MPRAGE sequence to normalize the SN due to variance of the brain size in each subjects [3]. T₁-MPRAGE image was scanned on a 1.5T (Avanto, Siemens) MR scanner. The used specific MR imaging parameters were: TR/TE = 1160/4.27 ms, flip angle = 15° and matrix size = 256x256, in-plane resolution was 0.9 mm iso-voxel. To make 3D SN and whole brain model, we have been manually segmented using software of 3D Slicer (<http://www.slicer.org>). To identify clear boundary of the SN, we adjust threshold value until the SN is separated from the adjacent structures (such as red nucleus or vessel). To calculate the normalized SN volume ratio, number of segmented ICV and SN voxel were counted. After then ICV and SN volume was measured by multiplying the number of voxels and voxel size. Finally, it was divided SN volume into ICV volume to get result of normalized SN volume ratio.

Results

Representative samples of 3D SN and whole brain model images of the normal control and PD, namely normal control and PD patient with an H&Y2 are selected and compared. Compared with PD patients and normal controls, 3D model of PD patients showed a shape change of the ventro-lateral boundaries and dorso-lateral boundaries (Fig. 1). As shown in ventral view the ventro-lateral surface of SN is smooth boundaries between the SN and CC (Crus Cerebri). However the ventro-lateral surface of the PD severely serrated. In this study, significant difference shape change was showed in the dorso-medial region of the SN. We were able to recognize inner structure of SN in normal controls. However these structures were absent in the PD patients as disease progressed. We supposed that this inner structure may be a nigrosome [1]. (see red arrow Fig.1) In general, volume of ventro-lateral aspect of the SN decrease in the PD patients compared with normal controls. However, the dorso-medial aspect of the SN seems to be filled in the PD patients. Fig.1 bottom is the 3D segmented results of whole brain.

Fig. 2. Shows a group difference which is calculated by normalized SN volume ratio of the individuals who participated in the experiment. In case of the normal control we averaged both (left and right) side while in the case of the PD patient, we measured only the most affected side value. Quantitative measurements revealed that the normalized SN volume ratio in PD patients [n=9, 2.252] were larger than those of the age-matched normal controls [n=9, 1.843] with statistical significance of P=0.002 (Fig.2 (A)). Fig.2 (B) showed the correlation to age between the PD patients and normal controls. As a result, there was substantial age dependent correlation. However, the age correlation pattern of PD patient group is different from normal control group. Comparing two correlation lines, the slope of the PD is -0.006 and normal control is 0.018. In addition to age dependent correlation we have also measured UPDRS motor score dependent correlation and the result is shown in Fig.2 (C). As the UPDRS motor score increase, the normalized SN volume ratio was decreased and the slope of correlation line was -0.021.

Discussion

This study demonstrates the potential of the 7.0T MRI for the quantification of volume changes in the SN. Especially, inner structure of the SN which is believed to be the nigrosomes was shown. The measured correlation analyses show that, in PD patients there is age dependent correlation and substantially UPDRS motor score dependent correlation. These statistical results would obviously be useful in setting the criteria for diagnosis of digression of PD patients in quantitative manner.

Acknowledgements

This work was supported by the Korea Science and Engineering Foundation (KOSEF) grant funded by the Korea government (MOST) (Grant no. 20100002134)

Reference

[1] P. Damier, et al., *Brain* 122(Pt 8) (1999) [2] Z.H. Cho, et al., *Movement Disorders* (2010), In press. [3] J. Eritaia, et al., *Magnetic Resonance in Medicine* 44:973-977 (2000)

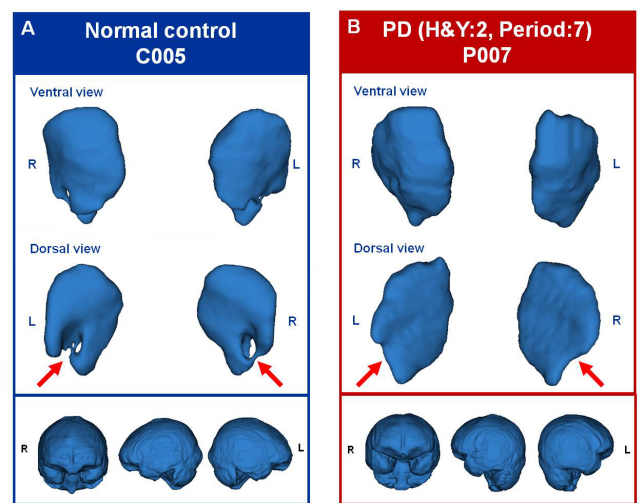


Fig 1. Segmented 3D model of the SN and whole brain from typical normal control and Parkinson's patient. (A) 3D model of the SN and whole brain in normal control. (B) 3D model of the SN and whole brain in PD patient. Red arrow indicates that inner structure of the SN change in PD. Bottom : 3D model of whole brain.

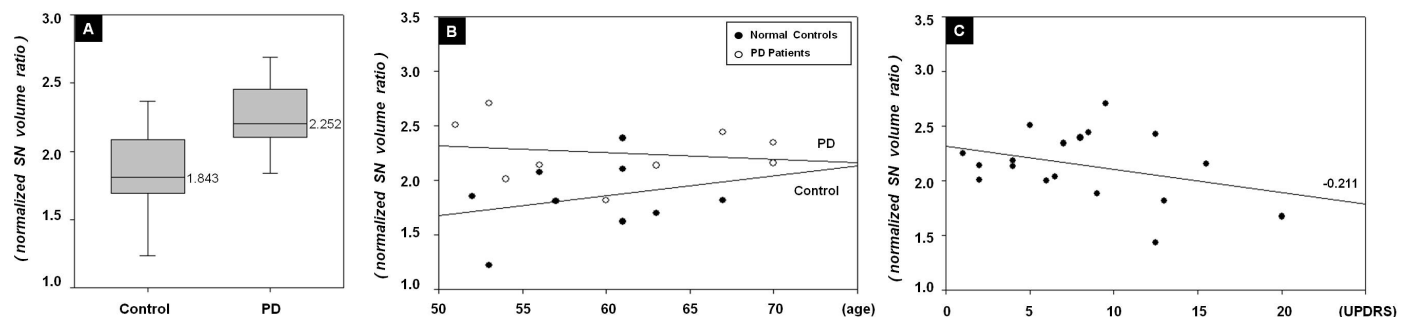


Fig 2. Results of analysis in typical PD patients and normal controls.