

# Ischemic Brain Damage and Loss of Ion Homeostasis During Focal Ischemia

F. E. Boada<sup>1</sup>, E. Nemoto<sup>2</sup>, Y. Qian<sup>3</sup>, C. Tanase<sup>4</sup>, C. Jungreis<sup>5</sup>, J. Weimer<sup>6</sup>, and V. Lee<sup>6</sup>

<sup>1</sup>Radiology and Bioengineering, University of Pittsburgh, Pittsburgh, PA, United States, <sup>2</sup>Neurosurgery, University of New Mexico, Albuquerque, New Mexico, United States, <sup>3</sup>Radiology, University of Pittsburgh, Pittsburgh, PA, United States, <sup>4</sup>Radiology, University of Pittsburgh, Pittsburgh, Pennsylvania, United States, <sup>5</sup>Radiology, Temple University, Philadelphia, Pennsylvania, United States, <sup>6</sup>Bioengineering, University of Pittsburgh, Pittsburgh, Pennsylvania, United States

## INTRODUCTION

The treatment outcome for acute brain ischemia using reperfusion therapies is strongly dependent on the physiologic status of the ischemic tissue since reperfusion of non-viable ischemic tissue carries increased risk of hemorrhage and/or edema formation. Non-invasive determination of tissue viability prior to reperfusion is, therefore, very desirable but there are no means to make this determination using current MRI tools. Tissue sodium concentration (TSC) increases during focal ischemia [1,2,3] and several reports suggest that once the TSC exceeds a threshold of about 65mM irreversible tissue damage (ITD) has already taken place [4,5,6]. The time at which this threshold is reached has been hypothesized to be variable [3,4] given the coupling between perfusion deficit, ATP production and NA-K-ATPase pump status. During evolving focal ischemia this coupling creates an extracellular sodium gradient and a concomitant diffusion-driven flux of sodium ions to the ischemic tissue (Fig. 1) at a rate that is expected to be proportional to the pump dysfunction. In this work, we investigate the relationship between sodium accumulation and perfusion deficit in a non-human primate (NHP) model of reversible focal ischemia and provide evidence that the threshold for ITD is perfusion dependent.

## METHODS

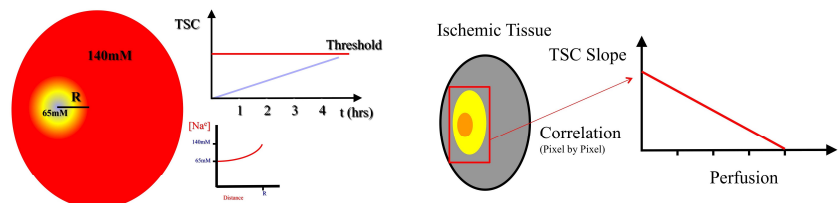
Temporary focal ischemia was induced on rhesus monkeys (N=5) by blocking the middle cerebral artery using an endovascular balloon catheter technique developed in our laboratory [7]. Upon establishing ischemia, the animals were transported to the MRI suite where serial angiographic (MRA), sodium (TSC), diffusion (ADC) and perfusion (PWI) MRI was performed continuously for 6hrs. All images were collected using pediatric imaging coils and a 3 Tesla clinical scanner. At 3 hours post ischemia, the balloon was removed and imaging continued until the animal was sacrificed under general anesthesia. Harvested brains were perfused, stained for infarction using immunohistochemistry (MAP2) [8] and digitized for pixel-by-pixel image analysis.

## RESULTS

Figure 2 presents axial slices from the (left-to-right) perfusion, diffusion, TSC maps at 3hrs post ischemia induction alongside the MAP2 histology image obtained after the animal was sacrificed. There is a clear area of perfusion and diffusion abnormality and an area of increased TSC. Pixel-wise correlations on this inherently spatially co-registered images were performed to establish: (a) the TSC value characterizes the tissue destined for infarction and (b) if the rate of TSC accumulation is perfusion dependent. Results from this analysis are presented in the bottom row of figure 2 where the (left) histogram of TSC values within the ischemic region and (right) the correlation between the rate of TSC increase and the perfusion signal immediately before reperfusion are presented. These plots show that tissue destined for infarction had a median of 60mM and that the rate of TSC accumulation (slope) increases as perfusion decreases.

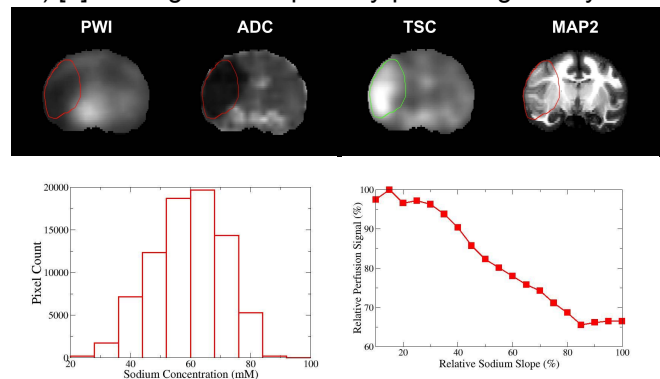
**CONCLUSIONS:** Our results support the thesis that: **elevated TSC (>65mM) significantly increases the risk of infarction** after tissue reperfusion and that the rate of TSC increase depends on the perfusion deficit. Consequently, **TSC might be helpful to predict low-risk reperfusion treatment windows on a subject-by-subject basis.**

**REFERENCES:** [1] Wang Y, et al.. Stroke. 2000; 31:1386-91. [2] Thulborn et al., A. Neuroimaging Clin N Am. 2005;15:639-53. [3] Jones et al. Stroke. 2006; 37:883-8. [4] Boada et al. Curr Top Dev Biol. 2005;70:77-101. [5] LaVerde et al. J Magn Reson Imaging. 2009;30:219-23. [6] Hussain et al. C. Ann Neurol. 2009; 66:55-62. [7] Jungreis et al.. AJNR Am J Neuroradiol. 2003;24:1834-6. [8] Kharlamov et al. J Neurosci Methods. 2009;182:205-10. **Supported in part by PHS Grant R01 NS44818**



**Figure 1: Sodium compartmentalization during brain ischemia. (left)** Concentration gradient creates a spatially dependent gradient leading to a diffusion-driven rise in TSC that is proportional to the perfusion deficit **(right)**.

At 3 hours post ischemia, the balloon was removed and imaging continued until the animal was sacrificed under general anesthesia. Harvested brains were perfused, stained for infarction using immunohistochemistry (MAP2) [8] and digitized for pixel-by-pixel image analysis.



**Figure 2: (top row) Coronal slices from volumetric PWI, ADC, TSC and MAP2 immediately before reperfusion.** Contours indicate the volume of infarction determined from the MAP2 histology images. These volumetric contours allow determination of the TSC histogram within the area destined for infarction **(bottom left)** and the relationship between the rate of TSC increase and the perfusion deficit **(bottom right)**