

# VALIDATION OF DIFFUSION WEIGHTED IMAGING OF CORTICAL ANISOTROPY BY MEANS OF A HISTOLOGICAL STAIN FOR MYELIN

M. Kleinnijenhuis<sup>1,2</sup>, K. J. Sikma<sup>1,3</sup>, M. Barth<sup>2,4</sup>, P. Dederen<sup>1</sup>, V. Zerbi<sup>1,5</sup>, B. Küsters<sup>6</sup>, D. Ruiter<sup>1,2</sup>, C. H. Slump<sup>3</sup>, and A-M. van Cappellen van Walsum<sup>1,7</sup>

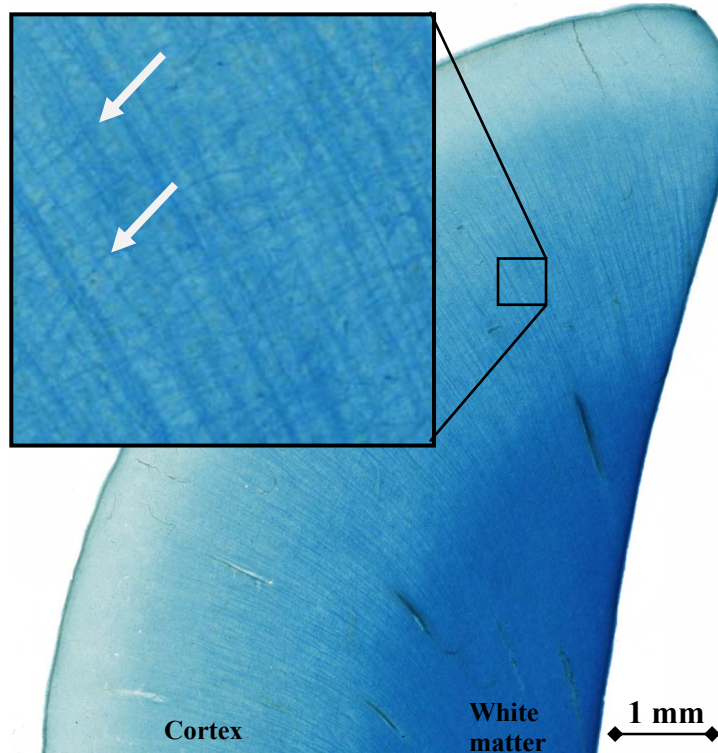
<sup>1</sup>Department of Anatomy, University Medical Centre St. Radboud, Nijmegen, Netherlands, <sup>2</sup>Donders Institute for Brain, Cognition and Behaviour, Radboud University Nijmegen, Nijmegen, Netherlands, <sup>3</sup>Signals and Systems, Faculty of Electrical Engineering, Mathematics and Computer Science, University of Twente, Enschede, Netherlands, <sup>4</sup>Erwin L. Hahn Institute for Magnetic Resonance Imaging, Essen, Germany, <sup>5</sup>Department of Radiology, University Medical Centre St. Radboud, Nijmegen, Netherlands, <sup>6</sup>Department of Pathology, University Medical Centre St. Radboud, Nijmegen, Netherlands, <sup>7</sup>MIRA Institute for Biomedical Technology and Technical Medicine, University of Twente, Enschede, Netherlands

## Introduction

Axonal membranes and myelin are known to be the main determinant of diffusion anisotropy in the brain [1]. Myelinated axons are present not only in white matter, but extend radially into the deeper cortical layers crossing with the tangentially oriented myelinated fibers also abundant in these layers [2]. Recently, several studies have shown anisotropy of water diffusion by Diffusion Weighted Imaging (DWI) in cortical grey matter [3,4]. Cortical anisotropy has been shown e.g. *ex vivo* in pigs [3] and *in vivo* in humans [4] at high magnetic field strengths allowing for the spatial resolution necessary. In the cortex, fiber orientation was found to be predominantly radial, but more complex architectures were also observed in the deeper layers [3]. To obtain a better understanding of anatomical connectivity *in vivo*, it would be very interesting to track fibers also in and into the cortex. However, the high isotropic component seen in the cortex by current low resolution *in vivo* DWI makes the estimation of cortical connectivity by tractography very challenging. In this study we aim to examine cortical fibers and also try to validate DWI results *in vitro*, as there are less practical limitations and a cross-validation with histological techniques (i.e. myelin staining) as the current gold standard is possible.

## Methods

Samples of human brain tissue (~3 cm<sup>3</sup>) containing both cortex and underlying white matter were obtained at autopsy (15h post-mortem), fixed in 10% buffered formalin and stored (>6 months) at 4 °C. Myelin staining of the tissue blocks was performed *en bloc* with Luxol Fast Blue (LFB), according to a protocol modified from [5]. Sections of 2mm thickness were stained for 72 h at 56 °C in saturated LFB solution to achieve full penetration of the dye. Differentiation time in 0.05 % LiCO<sub>3</sub> (aq) was 72 h. Samples were sectioned with a Leica vibratome at 100 µm, mounted on gelatin coated glasses and imaged at 20x magnification with a Zeiss microscope controlled by MicroBrightField software using the VirtualSlice module to create seamless high resolution images. A second sample was soaked in PBS (> 2 weeks) and imaged on a Bruker Biospec 11.7T system in Galden D05 perfluoroether. Diffusion Weighted Imaging was performed using a DW-SE sequence with segmented EPI read-out (TR=3.8s; TE=27ms; b-value=1500 s/mm<sup>2</sup>; 30 directions + 5 non-diffusion weighted; FOV = 30x30 mm, matrix size=64x64, 15 slices of 469 µm). For reconstruction of the orientation density function (ODF) Camino's mesd function was used (filter=PAS 1.4; mepointset=30). Multi-echo gradient echo (MGE) images were also acquired (3D FLASH; TR=70ms; TE=3-38ms; ΔTE=5ms; flip angle=30°; matrix size 256x256x256; FOV 30x30x30mm).




**Figure 1.** LFB stained section of somatosensory cortex imaged at 20x magnification. Inset: Arrows indicate two of the more prominent tangential fibers in the cortex

## Results and Discussion

The section of somatosensory cortex presented in Fig.1 shows a homogeneous staining of the white matter and excellent visualization of radii of myelinated fibers fanning out in the cortex. Moreover, tangentially oriented fibers are visible in the deeper cortical layers (inset). The DWI orientation density functions (Fig.2) seem to reflect these observations as well, with a single peak in white matter, and both a radial and a tangential peak in the cortex that decreases towards the outer layers.

## Conclusions

We have shown successful homogeneous myelin staining of blocks of human brain tissue that can be used to validate DWI of the cortex. These data suggest good qualitative agreement in fiber architecture between DWI and histology. The myelin staining might also allow for 3D reconstructions of the fiber architecture that can be quantitatively compared to DWI ODF reconstructions as was shown in 2D rat brain slices by [6].



**Figure 2.** Above: PAS ODFs in grey (left of yellow line) and white (right) matter. Left: MGE (average of echo1-5) showing GM/WM contrast and cortical layers. Box indicates zoomed section above.

[1] Beaulieu, NMR in Biomed. 2002 [2] Nieuwenhuys et al., The Human CNS 4<sup>th</sup> Ed. [3] Dyrby et al., HBM 2010 [4] Heidemann et al., MRM 2010 [5] Blackwell et al., NI 2009 [6] Leergaard et al., PLoS One 2010