

Effects of sustained high-altitude hypoxia on cerebral hydration and diffusion

J. S. Hunt, Jr.<sup>1</sup>, R. J. Theilmann<sup>1</sup>, B. C. Hsu<sup>1</sup>, E. Li<sup>1</sup>, Z. M. Smith<sup>1</sup>, M. Scadeng<sup>1</sup>, and D. J. Dubowitz<sup>1</sup>  
<sup>1</sup>Radiology, University of California San Diego, La Jolla, CA, United States

**Introduction:** Hypoxia associated with severe altitude sickness can result in cerebral edema. There is overlap of symptoms between cerebral edema and uncomplicated acute mountain sickness (AMS) suggesting a common etiology. However, the effects of uncomplicated acute mountain sickness on brain water content remain controversial. Previous studies at sea level in a hypoxic chamber (normobaric hypoxia) produced a mixed picture of cytotoxic and vasogenic edema [1-2] but acute studies at simulated high-altitude (hypobaric hypoxia) failed to show any alteration in brain water [3]. To investigate the impact of actual sustained hypobaric hypoxia on cerebral water content, we used 3T MRI measures of T<sub>2</sub> signal and ADC during two days and seven days at high altitude.

**Measurements:** We studied 17 healthy subjects (age 29.8 +/- 8.7 years, F=8, M=9). Cerebral T<sub>2</sub> signal was evaluated using a 3D FSE FLAIR sequence (TE=120ms, TR=10000ms, TI=2000ms, 26 slices, 4mm thick, 0.4mm gap, FOV 24cm, 320x256 matrix). Apparent Diffusions Coefficient (ADC) used a Double Spin Echo EPI diffusion weighted sequence (TE=76.7ms, TR=7000s, b=1000 s/mm<sup>2</sup>, 26 slices, 4mm thick, 0.4mm gap, 2 NEX, FOV 24cm, 128x128 matrix). A 3D FSPGR T1 weighted scan was used to co-register ROIs across scan sessions. Measurements were made at normoxia, and following 2 and 7 days sustained hypoxia at White Mountain Research Station (3,800m altitude, 90 Torr O<sub>2</sub>, mean SaO<sub>2</sub> 85.4% at 2 days, 87.9% at 7 days). Subjects remained hypoxic until after the MRI was completed. The order of the 2-day and 7-day exposure was random, with 2-13 months between measurements. Data were analyzed with repeated measures ANOVA and post-hoc T-test (significant at p < 0.05). Data are reported as mean +/- s.d.

**Analysis:** ROIs were manually selected in gray matter, white matter, basal ganglia (caudate nucleus), and corpus callosum (splenium) on the FSPGR baseline image. The baseline FSPGR was coregistered with 2- and 7-day FSPGR, and ROI rotated and applied to FLAIR and DWI MRI for each time point (baseline normoxia, two day, and 7 day hypoxia). Mean signal was established from a gaussian fit to the histogram of the intensity profile for each ROI. Mean FLAIR signal was normalized by FLAIR signal in vitreous humor of eyes. Subjects were grouped by Lake Louise Scores during the first 48 hours at altitude into two distinct groups; no AMS (LL score <=4) or clear symptoms of AMS (LL Score >=10). Subjects with intermediate values were not included in these groups.

**Results:** 6 subjects developed AMS, 8 subjects did not. In 3 subjects, Lake Louise AMS scores were intermediate, so they were not assigned an AMS grouping. All subjects showed a decrease in normalized T<sub>2</sub> signal from FLAIR images with duration of hypoxia. Mean signal change was -0.73 (+/- 0.15) for gray matter (p<0.05), -0.57 (+/- 0.082) for white matter (p<0.05), -0.59 (+/- 0.092) for basal ganglia (p<0.05), and -0.56 (+/- 0.12) corpus callosum (p<0.05). There was no significant difference between subjects with AMS versus no AMS for any ROI. There was no significant change in ADC for all regions irrespective of AMS status. Splenium of corpus callosum and caudate nucleus of basal ganglia showed small but non-significant ADC increases (+11 x10<sup>-6</sup> mm<sup>2</sup>/s, p=0.075 in splenium, +22 x10<sup>-6</sup> mm<sup>2</sup>/s, p=0.067 in caudate).

**Discussion:** Normobaric and hypobaric hypoxia appear to have different effects on brain water with reduction in T<sub>2</sub> signal during hypoxia seen during high altitude (hypobaric hypoxia) exposure. This may relate to lower barometric pressure, or effects of reduced hydration at altitude. No restricted diffusion with decreased ADC was seen for any subject, even those with significant AMS scores, in keeping with prior acute studies at simulated high-altitude [3], and in contrast to findings during normobaric chamber studies [1-2].

**Conclusions:** Cerebral T<sub>2</sub> signal and ADC studies provide a robust method to study brain water content and diffusion during sustained hypoxia. Our results indicate barometric pressure and hydration may be important covariables in the cerebral response to hypoxia.

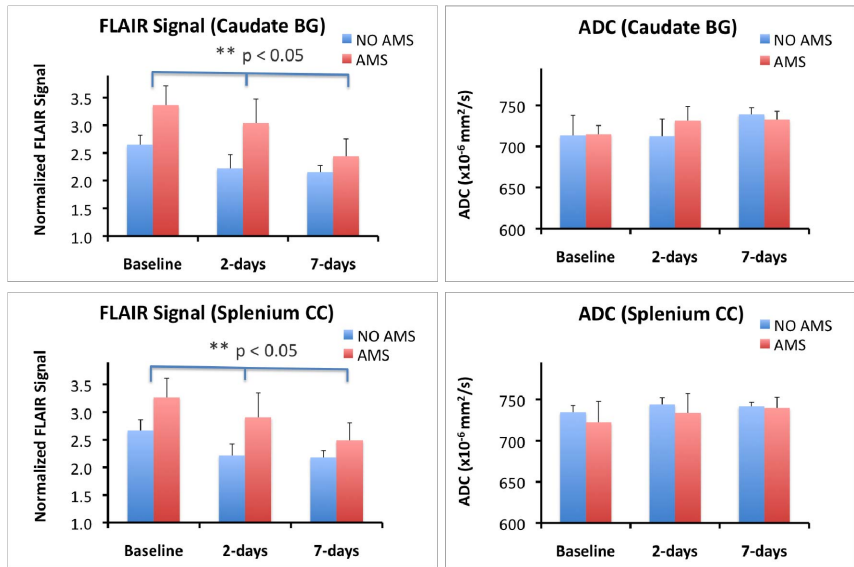


Figure shows FLAIR T2 signal (left) and ADC (right) in corpus callosum and basal ganglia during normoxia, 2-days and 7-days hypoxia. Red bars indicate subjects who suffered acute mountain sickness at altitude (blue bars indicate no mountain sickness). In all subjects T2 signal shows significant decline with duration of hypoxia in both regions (p < 0.05) but no significant difference with acute mountain sickness. ADC shows a small, but non-significant overall increase during hypoxia. (graphs display mean + standard error)

**References:** [1] Kallenberg et al. 2007. J Cereb Blood Flow Metab 27:1064-71. [2] Schoonman et al. 2008. J Cereb Blood Flow Metab 28: 198-206. [3] Fischer et al. 2004. Cephalgia 24: 66-71.  
**Supported by:** NIH R01 NS053934 (DJD)