

## Simultaneous intracranial EEG-fMRI in humans: data quality

D. W. Carmichael<sup>1</sup>, S. Vulliemoz<sup>1,2</sup>, R. Rodionov<sup>1</sup>, K. Rosenkranz<sup>1</sup>, A. McEvoy<sup>3</sup>, and L. Lemieux<sup>1,4</sup>

<sup>1</sup>Clinical and Experimental Epilepsy, UCL Institute of Neurology, London, United Kingdom, <sup>2</sup>Epilepsy Unit, University Hospital and University of Geneva, Geneva, Switzerland, <sup>3</sup>Victor Horsley Dept. Neurosurgery, National Hospital for Neurology and Neurosurgery, London, United Kingdom, <sup>4</sup>MRI Unit, National Society for Epilepsy, Chalfont St. Peter, United Kingdom

**Introduction:** Human brain activity recorded in epilepsy patients undergoing presurgical evaluation using intracranial electroencephalography (icEEG), allows for measurements with exquisite temporal resolution of rich dynamic activity from small regions of cortex. fMRI maps whole brain hemodynamic changes. We aimed to record icEEG and fMRI concurrently to study physiological and pathological activity at a greater range of spatial and temporal scales. However, technical challenges of safety [1] and data quality remain. In this abstract, the first results in two patients are presented with reference to safety and data quality.

**Methods:** Two patients undergoing presurgical evaluation with icEEG (#1: 76 subdural contacts, #2: 66 subdural contacts and 2x6 contact depth electrodes) were scanned with approval from the ethics committee of UCL/NHNN, and informed consent from the participants. We used the following: 1.5T scanner (Siemens Avanto, Erlangen Germany); head transmit/receive RF-coil; low-SAR sequences ( $\leq 0.1\text{W/Kg}$  head-average); exact external electrode cable configuration using a foam insert for reproducibility; 64-channels invasive EEG recorded with MR compatible equipment. We acquired a T1 volume and 2x10min EPI acquisitions (transverse, TE/TR=40/3000ms 38x2.5mm slices, 0.5mm gap, 3x3mm in-plane resolution) during rest. EEG was recording using a 2x32 channel MR compatible system located at the head end of the scanner and ECG was recorded using a 16 bipolar channel ExG MR compatible system located at the patient's feet. Carbon fibre leads were used for the EEG recording in addition to spatial separation to prevent potential interactions between the intracranial electrodes and leads with the ECG. Specific safety tests with this experimental configuration and exact scanning protocol were performed following published methods [1]. N.B. this constitutes 'off-label' use of the EEG, MRI and electrodes. Scanning-related artifacts on EEG were removed using the Brain Analyser V1.3 (Brain Products, Munich, Germany) implementation of the template subtraction and filtering algorithm [2]. EEG data quality was assessed firstly for cardiac-related artifacts by averaging of icEEG recorded within the MRI scanner based on the ECG R-peak and secondly for residual scanner-related artifact in patient #2 by comparison of EEG frequency-band power during EPI, without scanning inside the scanner, and outside the scanner. The electrode contact locations were determined from coregistered MRI and CT data (using spm5 [www.fil.ion.ucl.ac.uk](http://www.fil.ion.ucl.ac.uk)). EPI signal profiles were determined along a 30mm line normal to the grid surface originating at the contact (or radially from depth electrode contacts in patient #2). The mean, standard deviation and range of these profiles were calculated using Matlab ([www.mathworks.com](http://www.mathworks.com)). Additionally, the angle of the surface normal (giving the electrode angle relative to scanner's axes) was plotted and compared to the signal reduction at 5mm from the electrode contacts.

**Results:** For the equipment configuration and scanning protocol used in patients, in-vitro safety-tests showed that heating was  $\leq 0.1^\circ\text{C}$ . icEEG-fMRI was well tolerated and no adverse effect on the patients was observed including visual inspection (where possible) of the visible cortical surface on electrode removal. After gradient artifact correction, the intra-MR icEEG was comparable in visual appearance to that from extra-MR icEEG. Cardiac-related in-scanner artifacts were small in magnitude compared to epileptic spikes (Fig.1) and the spectral profiles compared to data recorded outside the scanner in patient #2 showed a significant difference during scanning in 1/18 of the contact and frequency-band combinations tested. MRI data acquired in patient #1 is shown in Fig. 2a and patient #2 in Fig. 2b. The image artifact under the electrode

contacts (as shown by the white dashed line box in Fig. 2a) is summarised for patient #1 in Fig. 2c. The relationship between the signal reduction and electrode contact angle relative to scanner axes (Fig. 2d) shows that signal reduction is associated with contacts at  $90^\circ$  to the z-axis and with an increasing angle relative to y-axis.

**Discussion:** Simultaneous icEEG-fMRI was performed without adverse health effects within specified and previously tested conditions. It was possible to obtain high quality EEG data using standard artifact correction methods. Cardiac-related EEG artifacts were smaller relative to the effects of interest than with scalp EEG, which might help elucidate their origin [3]. Using thin EPI slices ( $\sim 2\text{mm}$ ) with a short echo time (40ms) and echo spacing (500us) data was obtained that contained variable artifact levels. There was a relationship between the electrode angle relative to B0 and the dropout size for a frontal-cortical grid. This suggests that susceptibility effects are the main contributors to the signal degradation. We note that high-quality fMRI proximal to all electrodes is not essential for useful icEEG-fMRI, because exquisite measurements of brain activity are obtained at those locations with icEEG, while fMRI instead provides data where icEEG does not provide coverage. Nonetheless, on average  $>50\%$  of the EPI signal intensity was preserved 5mm from the electrode contacts, allowing for the study of co-localised fMRI responses. Further optimization of pulse sequences and improvements in electrode design can increase data quality in the future.

**References:** 1. Carmichael, D.W. *et al.* (2010). Feasibility of simultaneous intracranial EEG-fMRI in humans: a safety study. *Neuroimage*. 2. Allen, P. J., Josephs, O. & Turner, R. (2000). A method for removing imaging artifact from continuous EEG recorded during functional MRI. *Neuroimage*. 3. Yan WX, Mullinger KJ, Geirsdottir GB, Bowtell R. (2010). Physical modeling of pulse artifact sources in simultaneous EEG/fMRI, Hum Brain Mapp.

**Acknowledgments:** Medical Research Council (MRC grant G0301067). Swiss National Science Foundation and SNF 33CM20-124115 (SV).

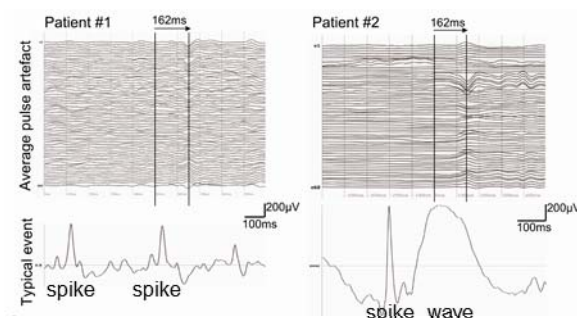


Figure 1 Pulse Artefact

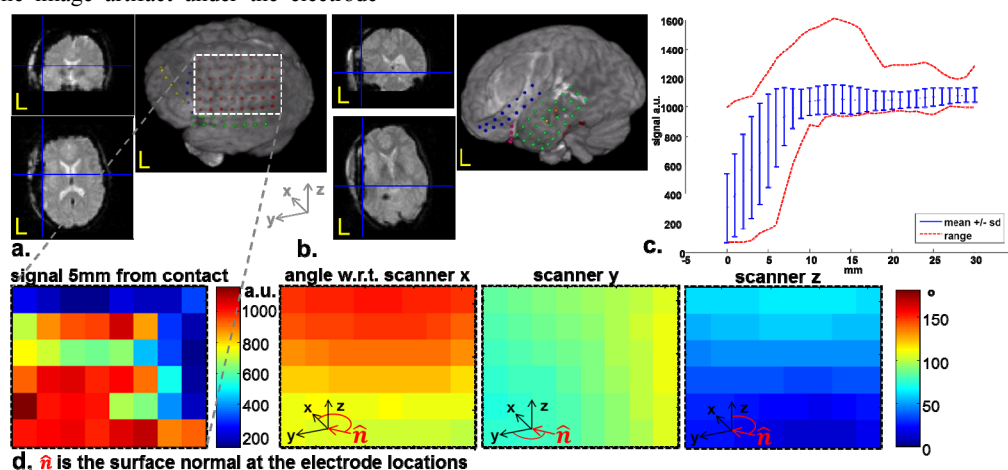


Figure 2 EPI data quality