

## Accuracy of MRI for the Assessment of the Geometry of Thoracic Stent Grafts

V. Rasche<sup>1</sup>, S. Trumpp<sup>1,2</sup>, A. Oberhuber<sup>2</sup>, N. Merkle<sup>1</sup>, K. H. Orend<sup>2</sup>, M. Hoffmann<sup>3</sup>, W. Rottbauer<sup>1</sup>, and A. Bornstedt<sup>1</sup>

<sup>1</sup>Internal Medicine II, University Hospital Ulm, Ulm, Germany, <sup>2</sup>Thorax and Vascular Surgery, University Hospital Ulm, Ulm, Germany, <sup>3</sup>Radiology, University Hospital Ulm, Ulm, Germany

**Background:** Thoracic Endovascular Aortic Repair (TEVAR) of various aortic pathologies has turned out as an attractive alternative to conventional surgical approaches. TEVAR may be associated with graft related complications such as endoleaks, kinking, infolding, and stentgraft migration, disconformability and disattachment phenomena. Therefore lifelong regular follow up by tomographic imaging is required for thorough monitoring of all patients, treated with thoracic aortic stent grafts. While multislice volumetric CT still represents the imaging gold standard for the assessment of implanted stent grafts, its related X-ray dose and the nephrotoxicity of the required contrast agent, limit its frequent application especially in younger patients and in patients with renal insufficiency. MRI has already proven its role for the follow-up of patients after endoluminally treated abdominal aortic aneurysm (1-5). The objective of this work was to prove the feasibility of MRI as a comprehensive imaging tool for the assessment of thoracic stent grafts, including disattachment phenomena, its dynamics over the cardiac cycle and its impact on vessel compliance.

**Methods:** Twenty consecutive patients (7 female, 13 male; mean age 36 +/- 15) were enrolled in this feasibility study. All patients initially presented with aortic rupture at the transition zone of the arch and descending segment of the thoracic aorta. The rupture site was treated with endovascular stent graft procedures in all patients. In 11 patients, a Medtronic Valiant stent graft and in 9 patients a Gore excluder TAG stent graft were implanted. All patients underwent conventional contrast agent (CA) enhanced routine CTA followed by the investigational MRI protocol, comprising a three-dimensional angiogram of the aorta with and without contrast enhancement and functional assessment of the stent motion over the cardiac cycle.

The quality of the resulting MRI and CTA data was directly compared by experienced MRI and CTA readers. The appreciation of the stent graft geometry  $Q_G$  was ranked on a 1 (poor) - 5 (excellent) scale and the deployment of the stent  $Q_d$  against the vessel wall was qualitatively assessed on a 1 (attached to the vessel wall) to 3 (large areas of the stent not attached to the vessel wall) scale. For comparison of the stent geometry the CTA data was registered to the MRA data by a landmark guided mutual information based registration technique (3D Slicer V3.6, <http://www.slicer.org>). After transformation of the CTA data, the resulting diameter of the stent was quantified at three locations along the stent graft in both modalities.

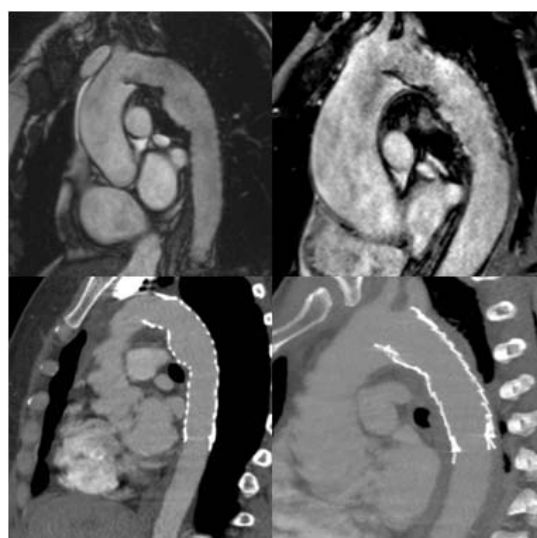


Figure 1: Appearance of the thoracic stent in MRI (top) and CTA (bottom).

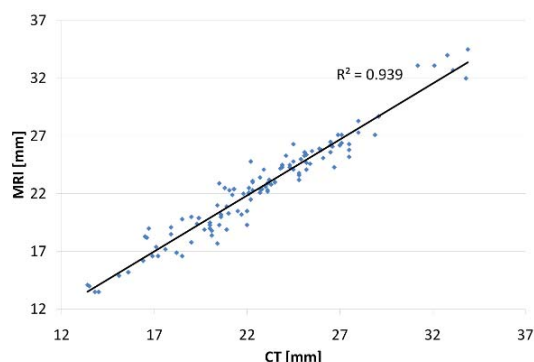


Figure 2: CT vs. MRI diameter measurements

**Results:** In all patients, MRI could provide the geometry of the stent graft with at least mediocre image quality (mean ranking  $Q_G = 4.2 \pm 0.75$ ). The dynamics of the stent were assessable in all patients (mean ranking  $Q_D = 3.7 \pm 0.76$ ). Although the image quality during systole suffered from superimposed flow artifacts in seven cases, the motion of the stent could be nicely appreciated over the entire cardiac cycle in all data sets. In several patients, motion of the stent was observed over the cardiac cycle. Excellent agreement ( $R^2 = 0.94$ ) between the MRI and CT derived values was found. Although not significant, a slight trend to overestimation of the diameter by MRI was observed. The intra-observer variability was  $-0.14 \pm 1\text{mm}$  ( $p=0.3$ ) for MRI and  $0 \pm 0.9\text{mm}$  ( $p=0.85$ ) for CT.

**Discussion:** MRI can provide a comprehensive assessment of thoracic aortic stent grafts after percutaneous implantation. The feasibility to assess stent graft geometry and smooth attachment to the vessel wall without any need for

ionizing radiation or nephrotoxic contrast agents, may MRI make a very attractive alternative to the current standard CTA as the imaging modality of choice for regular follow up in TEVAR patients.

**References:** (1) Merkle EM, et al. J Endovasc Ther 2002; 9 Suppl 2, I12-13; (2) Weigel S, et al. Eur Radiol 2003; 13(7):1628-34; (3) Farhat F, et al. J Thorac Cardiovasc Surg 2007;48(1):1-6; (4) Krämer SC, et al. Invest Radiol 2004;39(7):413-7; (5) Engellau L, et al. Eur J Vasc Endovasc Surg 1998;15(3):212-9.