

Magnetic Resonance Angiography (MRA) of the Calf Station at 3T: Intraindividual Comparison between Non-enhanced ECG-gated flow-dependent MRA, Continuous Table Movement MRA and Time-Resolved MRA

S. Haneder¹, U. I. Attenberger¹, P. Riffel¹, T. Henzler¹, S. O. Schönberg¹, and H. J. Michaely¹

¹Institute of Clinical Radiology and Nuclear Medicine, University Medical Center Mannheim, Mannheim, Germany

Introduction:

Over the last years magnetic resonance angiography (MRA) has developed as the favored non-invasive diagnostic imaging modality particularly in the peripheral vascular system. Currently, contrast-enhanced magnetic resonance angiography (CE-MRA) during the first pass of standard, gadolinium-based contrast agents (GBCA) is the most widely used technique. Yet, these MRA-techniques depend on the intravenous administration of GBCAs which were linked to the occurrence of nephrogenic systemic fibrosis (NSF) in patients with severe renal failure. Particularly in these patients, MRA without administration of GBCA is highly desirable. A recent technical approach for non-enhanced MRA¹ exploits the signal difference of arterial and venous blood based on the different flow velocities during the cardiac cycle and is recently commercially available (*nativeSPACE*, Siemens Healthcare Sector). This non-contrast-enhanced MRA (NE-MRA) uses an ECG triggered three-dimensional partial Fourier acquisition fast spin echo sequence. The purpose of this study was therefore to assess the clinical robustness of a novel non-enhanced MRA and to compare its image quality to two contrast-enhanced techniques: a low-dose contrast-enhanced, continuous table-movement-MRA (CTM-MRA) and a time-resolved TWIST-MRA in a single MR-exam at 3.0T.

Method and Materials:

36 consecutive patients (mean age 66.1 ± 14.4 years, 27 men/ 9 women) suffering from PAOD (stages II-IV) were included in this prospective, IRB approved study. All studies were performed on a single 32-channel whole-body 3.0T MR system (MAGNETOM Tim Trio, Siemens Healthcare Sector). During a single MR-exam, patients underwent NE-MRA (*nativeSPACE*, TR=2R-R intervals/ TE=34ms/1.3mm isotropic resolution) of the calf station as well as contrast-enhanced CTM-MRA (TR=2.4ms/ TE=1.0ms/ 1.2mm isotropic resolution) and TWIST-MRA (TR=2.8ms/ TE=1.1ms/ 1.1mm isotropic resolution). As preparatory sequence for the NE-MRA to determine the systolic and diastolic ECG trigger delay (TD) an inversion recovery 2D ECG-gated half-Fourier fast spin echo sequence with TD intervals of 50ms ranging from 0ms to 900ms was acquired. Based on the results of this measurement, the systolic and diastolic delay times were established using the system's MeanCurve tool. For the contrast-enhanced CTM-MRA and TWIST-MRA a combined low-dose protocol² was acquired with a total of 0.1 mmol/kg BW gadobutrol at 1.5 mL/s (70% for CTM-MRA and 30% for TWIST-MRA).

The image quality (IQ) as well as the degree of stenoses were rated on a four point scale (4=excellent-1=non-diagnostic; 4=occlusion-1=insignificant wall changes). Positive (PPV) and negative predictive values (NPV), sensitivity (SS) and specificity (SP) for stenoses detection were calculated for NE-MRA vs. CTM-MRA and NE-MRA vs. TWIST-MRA. Values were obtained for overall graduation of vessel wall changes and for severe stenoses (>70%).

Results:

With NE-MRA 122/288 (42.4%) segments were not assessable due to patient motion. Compared to CTM-MRA and TWIST-MRA the IQ was significantly inferior (p<0.0001 to p=0.0426). CTM-MRA/TWIST-MRA detected stenoses in 44.9%/46.1% of patients, whereof 85.0%/82.9% were high-grade stenoses. NE-MRA detected stenoses in 53.5% of patients, thereof 94.0% high grade. SS/NPV of the NE-MRA ranged from 97.8% - 100%. The SP and PPV ranged from 72.7% - 85.5% and 66.7% - 78.2%.

Conclusion:

In conclusion, this study demonstrates that contrast-enhanced CTM-MRA and TWIST-MRA are superior to NE-MRA in the calf station. The NE-MRA is very susceptible to motion rendering it non-diagnostic in almost 50% of all patients. If diagnostic however, the NE-MRA has an excellent sensitivity and negative predictive value, making it a good screening sequence.

References:

1. Miyazaki M, Takai H, Sugiura S, et al. Peripheral MR angiography: separation of arteries from veins with flow-spoiled gradient pulses in electrocardiography-triggered three-dimensional half-Fourier fast spin-echo imaging. Radiology. 2003;227:890-896.
2. Voth M, Haneder S, Huck K, et al. Peripheral magnetic resonance angiography with continuous table movement in combination with high spatial and temporal resolution time-resolved MRA With a total single dose (0.1 mmol/kg) of gadobutrol at 3.0 T. Invest Radiol. 2009;44:627-633.

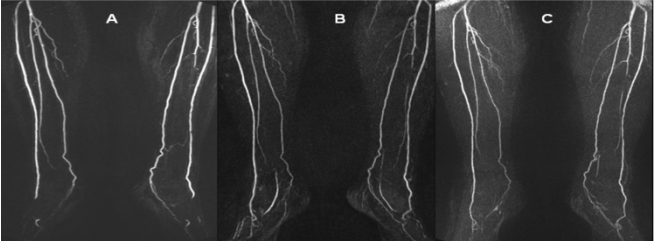


Figure 1. These coronal MIP images in a 70 year old female patient demonstrate equal excellent image quality of the A. NE-MRA, B. CTM-MRA and C. TWIST-MRA.

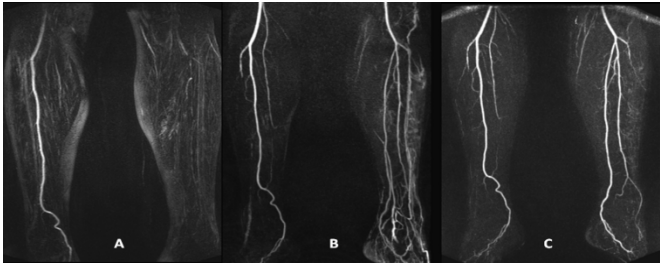


Figure 2. In this 65 year old male patient the image quality of the left distal lower extremities with the A. NE-MRA is non-diagnostic due to motion artifacts compared to the diagnostic quality with the B. CTM-MRA and C. TWIST-MRA.

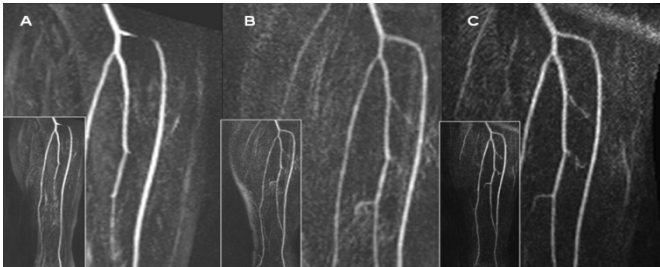


Figure 3. An occlusion of the proximal left anterior tibial artery was detected in this 65 year old male patient in the A. NE-MRA, which was not confirmed in the both contrast-enhanced techniques B. CTM-MRA and C. TWIST-MRA.

Table 1. Comparison of NE-MRA vs. CTM-MRA and TWIST-MRA for the Overall Graduation of Vessel Wall Changes and for the Detection of High Grade (>70%) Lesions

	Scenario I				Scenario II			
	Overall Graduation		High Grade Stenoses (>70%)		Overall Graduation		High Grade Stenoses (>70%)	
	vs. CTM-MRA	vs. TWIST-MRA	vs. CTM-MRA	vs. TWIST-MRA	vs. CTM-MRA	vs. TWIST-MRA	vs. CTM-MRA	vs. TWIST-MRA
SS [%]	100	100	100	100	98.2	97.8	100	100
SP [%]	80.5	81.5	85.5	85.4	72.7	73.5	78.8	79.4
PPV [%]	72.9	74.6	77.8	78.2	66.7	68.3	73.1	74.4
NPV [%]	100	100	100	100	98.6	98.6	100	100

Note - Scenario I = If one leg was not assessable in the NE-MRA, the patient was excluded
Scenario II = If one leg was not assessable in the NE-MRA, only these segments were excluded
SS = Sensitivity, SP = Specificity, PPV = Positive Predictive Value, NPV = Negative Predictive Value