

Dynamic T2prep for flow-independent vessel wall imaging

M. E. Andia¹, and R. M. Botnar¹

¹Division of Imaging Sciences and Biomedical Engineering, Kings College London, London, United Kingdom

INTRODUCTION: Bright-blood coronary magnetic resonance angiography (MRA) has shown great potential for non-invasive assessment of intraluminal coronary artery disease, however angiography provides minimal information on the magnitude of underlying atherosclerotic plaque. Recent MSCT [1] and IVUS [2] studies have shown that the underlying lesion in patients with ACS demonstrates extensive outward remodelling as well as CT and echo attenuation compared to those with stable angina [3]. In addition, plaque burden was found to be a good predictor for future coronary events [4]. These findings suggest that direct plaque visualization may have potential to identify patients with a high risk of future coronary events and thus may help to better guide therapy. Black-blood MRI techniques have been successfully applied to visualize the vessel wall of the aorta and coronary arteries [5][6][7]. The main limitation of these techniques is that they rely on blood flow. In this work we present a *flow-independent* MR vessel wall technique based on the differences in T2 relaxation time of arterial blood and surrounding tissues using a T2prep prepulse [8]. **METHODS:** The main characteristic of the T2prep prepulse is that it increases contrast between arterial blood and myocardium (and vessel wall) based on their T2 differences ($T_{2\text{arterial blood}}=250$, $T_{2\text{myocardium}}=50\text{ms}$). Signal from tissues with a shorter T2 relaxation time decay faster while signal from tissues with longer T2 will be maintained. Because arterial blood has a long T2, its signal only decays slowly while signal of muscle and the vessel wall decays more rapidly. Subtraction of two data sets, one obtained with T2prep(+) and another without T2prep(-) allows nulling the signal of arterial blood while maintaining the signal of muscle and vessel wall (Figure 1). The dynamic-T2prep pulse sequence (Figure 2, $\text{dyn1}=\text{T2prep}(+)$, $\text{dyn2}=\text{T2prep}(-)$) was implemented on a 3T Achieva Gyroscan MR scanner (Philips Healthcare, Best, NL) equipped with a 32 channel receiver coil. A simulation of the longitudinal magnetization after subtraction for different tissues and for different T2prep durations (T_{Eff}) is shown in Figure 3. The

Figure 1- Schematic representation of the dynamic T2prep. Without T2prep = T2prep(-) and with T2prep = T2prep(+).

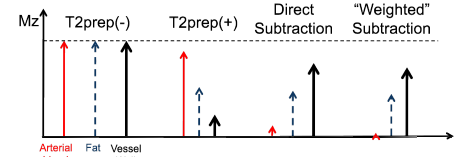


Figure 2- Diagram of the MR implementation of dynamic-T2 prep.

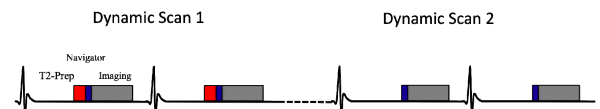


Figure 3- Simulation of the Mz magnetization for different tissues of the dynamic T2prep for different T2prep durations (T_{Eff}). (a) Mz before the imaging sequence when T2prep(+) (b) Mz when T2prep(-). (c) Difference between T2prep(-) and T2prep(+). (d) Magnetization after subtraction for optimal T2prep duration of $T_{\text{Eff}}=60$ ms.

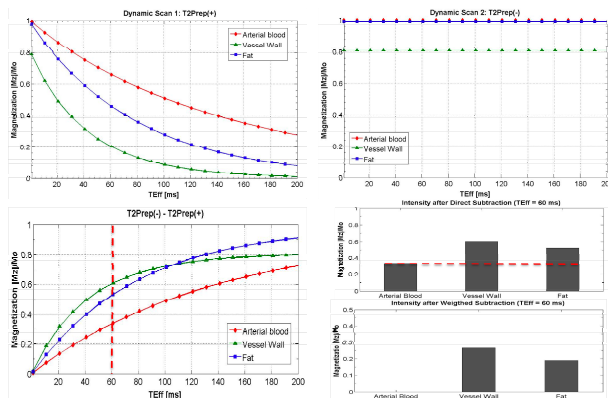
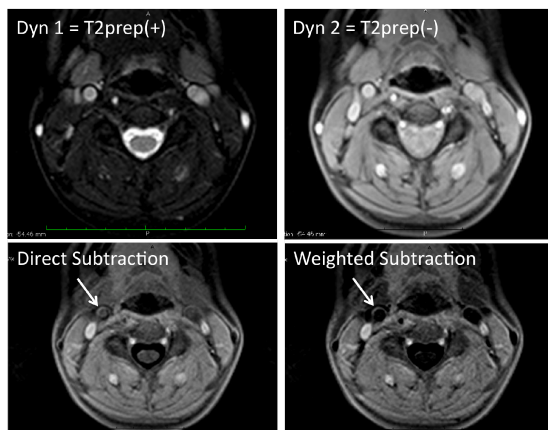


Figure 4- Flow-independent black blood images of carotid vessel wall using the dynamic-T2prep sequence



maximum contrast between muscle and arterial blood

is reached at $T_{\text{Eff}} = 60$ ms; Figure 3d shows the expected contrast between arterial blood, vessel wall (muscle) and epicardial fat in subtracted images. **RESULTS:** We successfully applied the dynamic-T2prep in four healthy volunteers and obtained black blood vessel wall images of the aortic, carotid and left coronary artery vessel wall. Representative images of the carotid (Figure 4), aortic and coronary vessel wall of direct and weighted subtractions are shown in Figure 5. The weighting factor was adjusted to null the residual magnetization in arterial blood as demonstrated in Figure 1 and 3. **CONCLUSIONS:** We demonstrate a new approach for flow-independent vessel wall imaging. Our initial results show good delineation of the vessel wall in the great vessels and some motion sensitivity due to subtraction in the coronary arteries. Ongoing work will address the issue of bulk motion sensitivity.

REFERENCES: [1] Motoyama S JACC 2009 [2] Wu X Am J Cardiol 2010 [3] Conti CR Clin Cardiol 2010 [4] Kubo T JACC 2009 [5] Fayad ZA Circulation 2000 [6] Botnar RM Circulation 2000 [7] Kim WY Circulation 2002 [8] Brittain JH MRM 1995

Figure 5- Flow-independent black blood images of aortic and left coronary artery vessel wall using the dynamic-T2prep sequence

