

In Vivo Assessment of Abdominal Aortic Aneurysm in the elastase-induced mouse model

M. A. Bartoli¹, F. Kober¹, P. J. Cozzone¹, and M. Bernard¹

¹Centre de Resonance Magnetique Biologique et Medicale, Faculte de Medecine, Universite de la Mediterranee, Marseille, Provence, France

Introduction

Abdominal aortic aneurysms (AAAs) are a common and potentially life-threatening condition associated with advanced age, cigarette smoking, atherosclerosis, and an inherited predisposition. The elastase perfusion mouse model is one of the most reliable animal models of AAA formation. So far, there are no non-invasive or longitudinal studies measuring aortic diameter and wall thickness. High-field MRI is ideal for vascular research because it can generate high resolution images across many time-points. This MRI study at 11.75T aimed at evaluating the reliability of longitudinal *in vivo* aortic diameter and wall thickness measurements in mice after aortic perfusion with elastase or with heat-inactivated elastase in control animals.

Methods

Eighteen adult male C57BL/6 mice underwent transient elastase (n=9) or heat inactivated elastase perfusion (n=9) of the abdominal aorta to induce the development of AAAs. During mouse surgery, aortic diameters were measured with a calibrated ocular grid at a resolution of 0.01 mm. The extent of aortic dilatation was measured before and immediately after elastase perfusion (day 0) and again at day 14. Two animals from the elastase group and one animal from the control group died before the second MR examination. MRI was performed on a Bruker AVANCE 500 wide bore spectrometer (11.75 T). An angio FLASH sequence (TR=100ms) was used to visualize the aorta two longitudinal planes. These images served as basis for perpendicular slice positioning of the vessel-wall imaging sequence (respiratory-gated multi-slice spin-echo, TR ~ 1500ms, TE=8ms, in-plane resolution: 117 x 117 μm^2 , slice thickness: 0.5 mm, duration 12 minutes). Multi-slice FLASH imaging was then used to acquire positive-blood-contrast images from the same slices. Mice underwent MRI at day 0 just before initial surgery and at day 14 before harvest and AAA maximum diameter measurement with ocular grid. Aortic diameter and wall thickness were obtained by manually tracing inner and outer regions that were fitted to circular shapes of the same area (ImageJ). Diameter and thickness were calculated from these circles.

Results

Figure 3 shows the typical elastase AAA profile (gray: inner, black: outer vessel diameter) versus slice number. This model does not produce abrupt changes along the aorta. The maximum aortic diameter along the measured series was significantly greater in elastase-perfused mice compared to controls with both the optic grid measurement (1.157 ± 0.143 mm vs 0.929 ± 0.069 mm, $p=0.038$) and the MRI measurement of the outer diameter (1.204 ± 0.086 mm vs 1.067 ± 0.057 mm, $p=0.0029$). A comparison between optic and MRI measurements (pooled data) showed good correlation ($p=0.0001$, $R^2=0.88$, figure 4). Aortic wall area was also significantly different in elastase perfused mice compared to control mice (0.572 ± 0.135 mm² vs 0.454 ± 0.085 mm², respectively $p=0.0205$).

Conclusion

These results show the feasibility of following aneurismal development after aortic elastase perfusion using MRI through good correlation with optical measurements. This approach might help in better understanding the pathologic mechanisms that contribute to aneurismal degeneration and for developing new therapeutic approaches.

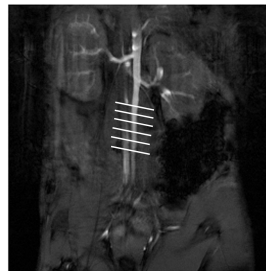

Figure 1

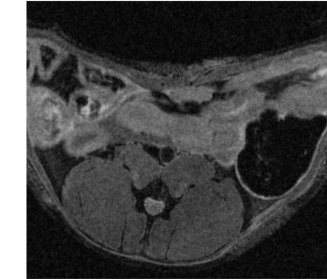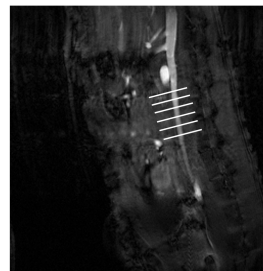


Figure 2

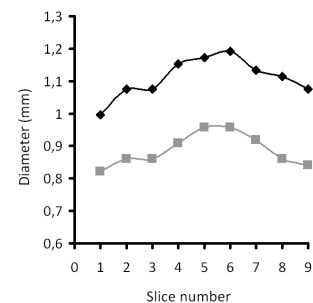


Figure 3

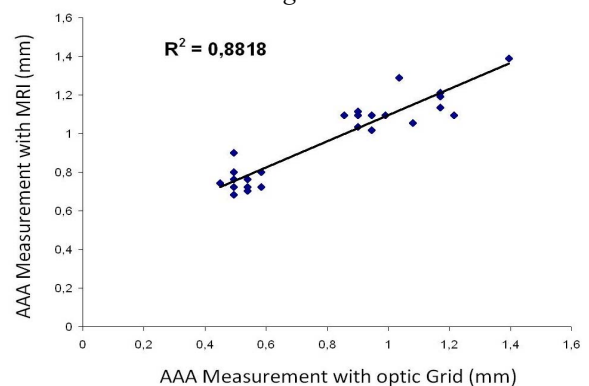


Figure 4