

The added value of a bi-exponential approach for processing multi-b diffusion-weighted imaging data in the diagnosis of hepatic tumors

S. Doblas¹, M. Wagner^{1,2}, J.-L. Daire^{1,2}, N. Haddad^{1,2}, H. Leita^{2,3}, R. Sinkus¹, V. Vilgrain^{1,2}, and B. E. Van Beers^{1,2}

¹Centre de Recherche Biomédicale Bichat-Beaujon, INSERM U773, Clichy, France, ²Department of Radiology, Beaujon University Hospital, University Paris Diderot, Clichy, France, ³Department of Radiology, Hospitais de Universidade de Coimbra, Coimbra, Portugal

Introduction: Diffusion-weighted imaging (DWI) has shown a great potential to help distinguish benign from malignant tumors. The higher cellularity of malignant lesions is indeed reflected in low apparent diffusion coefficients (ADC) while benign lesions present less diffusion restrictions with accompanying high ADC. However, such a classical approach fails to identify tumor types [1] and a more thorough approach using bi-exponential fitting of diffusion data can be adopted to extract microcirculation perfusion (which dominates at low b values) and pure molecular diffusion (of importance at high b values) information [2]. Here, mono-exponential and bi-exponential schemes were compared for the characterization of human hepatic tumors on a cohort of 89 patients.

Material and methods: MR imaging sessions were conducted on a 1.5T Philips clinical MRI system (Philips Medical Systems, Best, The Netherlands). In addition to routine morphological acquisitions, consenting patients (n = 89) were subjected to conventional dynamic contrast-enhanced (DCE) imaging as well as multi-b DWI. The study included 48 benign (10 hemangiomas, 9 cysts, 20 FNH and 9 adenomas) and 46 malignant tumors (12 metastases, 27 HCC and 7 cholangiocarcinomas). DWI free-breathing acquisition followed a spin-echo scheme with a EPI readout (TR/TE = 305/56 ms, field of view of 320 × 320 mm² for a 80 × 80 matrix, 3 transverse slices of 4 mm of thickness) providing DW images for 11 b values (0, 10, 20, 30, 40, 50, 75, 100, 150, 300 and 500 s/mm²). Specific regions of interest (ROI) were determined for each tumor, as “global” (i.e. encompassing the whole tumor) and “viable tumor” (i.e. presenting maximal enhancement on arterial or portal venous DCE images). Signal intensities (SI) of these ROIs were fitted to a mono-exponential form ($SI = SI_0 \cdot \exp(-b \times ADC_{mono})$) or a bi-exponential form ($SI = DC_{fast} \cdot \exp(-b \times ADC_{fast}) + DC_{slow} \cdot \exp(-b \times ADC_{slow})$), to extract the classical ADC (ADC_{mono}) as well as the perfusion (DC_{fast}) and pure diffusion (ADC_{slow}) fractions of the signal, the perfusion (ADC_{fast}) and pure diffusion (ADC_{slow}) coefficients.

Results: ADC_{slow} and ADC_{mono} were lower in malignant lesions ($1.17 \pm 0.29 \cdot 10^{-3} \text{ mm}^2/\text{s}$ and $1.62 \pm 0.39 \cdot 10^{-3} \text{ mm}^2/\text{s}$, respectively) than in benign tumors ($1.41 \pm 0.38 \cdot 10^{-3} \text{ mm}^2/\text{s}$ and $2.01 \pm 0.71 \cdot 10^{-3} \text{ mm}^2/\text{s}$), whereas the other parameters were similar in both subgroups. This distinction between benign and malignant lesions was not affected in any way by the type of ROI which was considered, and was similar whether ADC_{mono} or ADC_{slow} were assessed (Fig. A). When comparing tumor types, metastases were found to have a lower perfusion fraction (0.18 ± 0.05) and a higher pure diffusion fraction (0.83 ± 0.06) than HCC, FNH and hemangiomas (Fig. B; for example, $DC_{fast} = 0.23 \pm 0.08$ and $DC_{slow} = 0.76 \pm 0.08$ for HCC). Besides, ADC_{slow} (Fig. B) and ADC_{mono} both were able to distinguish FNH from HCC and cholangiocarcinomas.

Conclusion: To differentiate benign lesions from malignant ones based on multi-b DWI data, it is sufficient to consider a global ROI, without subdividing the tumor. The presence of necrosis or fibrotic parts did not seem to affect the overall diffusion parameters. Besides, a more thorough approach such as the bi-exponential fitting presented here did not offer any added value with respect to the distinction between benign and malignant lesions. However, both perfusion and pure diffusion fractions helped to differentiate metastases as a specific tumor subgroup, which would point out that the bi-exponential approach can have some advantages in specific cases.

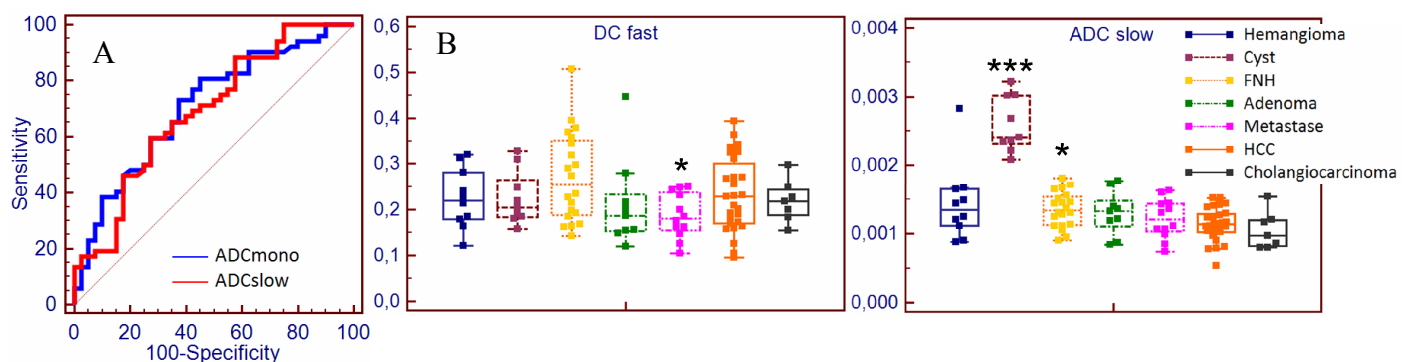


Fig. A: ROC curves for the test benign versus malignant tumors; Fig. B: Box plots of DC_{fast} and ADC_{slow} (mm^2/s) of each tumor type (DC_{fast} : * $p < 0.05$ (ANOVA) between metastases and HCC/FNH/hemangiomas; ADC_{slow} : * $p < 0.05$ between FNH and HCC/cholangiocarcinomas; *** $p < 0.001$ between cysts and every other tumor type (ANOVA)).

1. F.H. Miller *et al.*, J MRI 32 : 138 (2010)
2. D. Le Bihan, Radiology 161 : 401 (1986)