

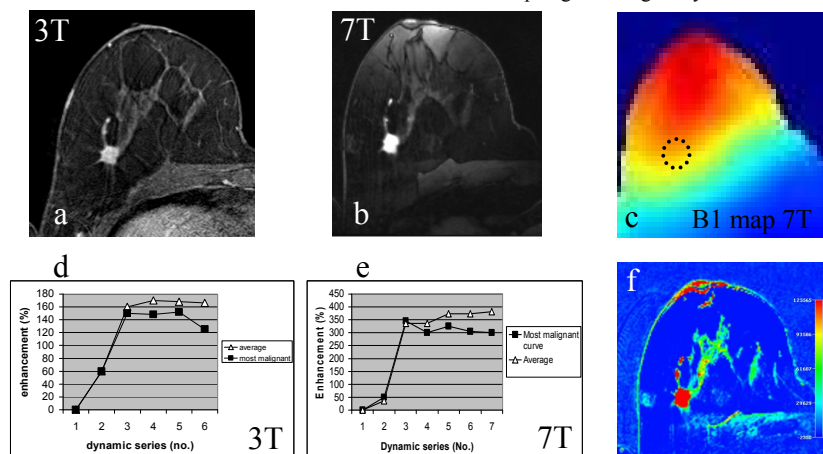
## 7T versus 3T Contrast-Enhanced Magnetic Resonance Imaging of invasive breast cancer

B. L. Stehouwer<sup>1</sup>, D. W. Klomp<sup>1</sup>, M. A. Kortweg<sup>1</sup>, P. R. Luijten<sup>1</sup>, W. P. Mali<sup>1</sup>, M. A. van den Bosch<sup>1</sup>, and W. B. Veldhuis<sup>1</sup>

<sup>1</sup>Radiology, UMCU, Utrecht, Netherlands

**Introduction** Recently ultra-high field 7Tesla (7T) MRI has become clinically available. 7T breast MRI offers new diagnostic possibilities that have the potential to improve the staging of breast cancer patients. For instance the ability to study phase related changes for the detection of calcifications or ultra high resolution imaging for improved morphology assessment. However, higher field strengths are also associated with limitations[1], such as increased B1 field inhomogeneity, which may interfere with the interpretation of enhancement kinetics that is central to the currently achieved diagnostic accuracy. In this study we report our first experience with clinically performed contrast-enhanced (CE) breast MRI at 7T, and directly compared the imaging findings with those obtained at 3T.

**Materials and Methods** A 52 year old female was included with a mammographically suspicious irregular mass with spiculated margins (BI-RADS V) in the right breast (figure 2b). 7T MRI was performed prior to large core needle biopsy to prevent biopsy artifacts. 3T imaging was performed according to our standard clinical breast imaging protocol. MRI was performed on a whole body 7T scanner (Philips Health Care, Cleveland, USA) using a two-channel double tuned unilateral RF dedicated breast coil. The patient was placed in prone position with the cup shaped breast coil placed directly below the right breast. The scan protocol included a 3D T1 weighted (T1w) turbo field echo sequence with fat suppression by means of selective water excitation (WATS) [TR/TE 10/2.0ms, flip angle 10°, FOV 160x160x160mm<sup>3</sup>, acquired resolution 1x1x2 mm<sup>3</sup>]; a dynamic series consisting of 7 consecutive 3D T1w TFE WATS sequences [TR/TE 5.0/2.0ms, flip angle 20°, FOV 160x160x160 mm<sup>3</sup>, acquired resolution 1mm isotropic, temporal resolution of 63 seconds]; and a high resolution T1w 3D Fast Field Echo (FFE-gradient echo) sequence with fat suppression by means of Spectral Selection Attenuated Inversion Recovery (SPAIR) [TR/TE 7.0/2.9ms, flip angle 12°, FOV 120x120x120 mm<sup>3</sup>, acquired resolution 0.45x0.57x0.45mm<sup>3</sup>]. During the dynamic series 0.1mmol/kg gadobutrol (Gd) was manually injected intra venously during the beginning of the second series followed by a 20cc saline flush. The 3T MRI (Philips Health Care, Cleveland, USA) protocol included a T1w 3D FFE SPAIR dynamic sequence [TR/TE 3.1/1.7ms, flip angle 10°, FOV 360x360x150 mm<sup>3</sup>, acquired resolution 1.1x1.1x2.4mm<sup>3</sup>, temporal resolution of 60 seconds]. During this sequence 0.1mmol/kg Gd was injected with an auto injector. The increase in signal to noise ratio (SNR) of the mass after enhancement was calculated at both field strengths. Morphology of the lesion and contrast-enhancement kinetics were described according to the MRI-BIRADS lexicon. The results were compared to final pathological analysis. Phantom measurements were conducted at 7T to evaluate the B1 field flip angle homogeneity.



**Fig 1:** CE-MRI results obtained at 3T (a,d) and 7T (b,c,e,f). Note the enhanced SNR as well as the contrast between the tumor and glandular tissue at 7T (b) versus 3T (a). Enhancement curves (d,e) show similar rapid initial rise and a wash-out pattern in the delayed phase for the most malignant curve according to the BI-RADS criteria (black squares). The average curve showed a plateau type pattern at both field strengths (white triangles). Due to saturation at higher etc. shown 'plateau' type of curve on both field strengths (white triangular curves). Due to increased saturation at higher flip angles (i.e. signal inverse related to B1) the non uniformity in receive sensitivity (c) is greatly compensated, as reflected in the color map obtained without any image correction (f).

**Results** The phantom measurements showed a reasonably homogenous B1 field with optimal flip angles near the areola and suboptimal flip angles closer towards the chest wall (figure 1c). The 7T MRI examination was well tolerated. Good contrast between mass and surrounding fat and fibroglandular tissue was obtained. Following contrast injection the mass showed homogenous enhancement (figure 1b,f). The most malignant kinetic curve at 7T showed a rapid initial rise to a peak signal intensity 345% higher than the baseline, followed by a wash-out delayed phase (10,11% wash-out): a "type 3" or "malignant type of curve" (figure 1e). The SNR of the mass before injection was 42. During peak enhancement in the 2<sup>nd</sup> series after injection of contrast agent, the SNR increased to 194; an 462% increase. The highest resolution, post-contrast sequence showed a 1.3x1.4x1.4cm<sup>3</sup> irregular mass, with spiculated margins (figure 2a). No other suspicious lesions were detected in the right breast. The lesion was categorized as BI-RADS V, i.e. highly suspicious for malignancy. The 3T images were of high quality as well. Following contrast injection the mass showed homogenous enhancement (figure 1a). The most malignant kinetic curve at 3T showed a rapid initial rise to a peak signal intensity 150% higher than the baseline, followed by a wash-out delayed phase (16,66% wash-out): a "type 3" or "malignant type of curve" (figure 1d). The SNR of the mass before injection was 17. In the 2<sup>nd</sup> series after contrast injection the SNR was 48; an 282% increase. The depicted irregular spiculated mass measured 1.2x1.4x1.5cm<sup>3</sup>. Because the 3T imaging took place after large core needle biopsy, the lesion was categorized as BI-RADS VI, i.e. known malignancy. Tumor morphology and lesion size determined at final pathological analysis corresponded to the 7T and 3T measurements. The tumor mass was a ductalobular carcinoma with a component of carcinoma in situ.

**Conclusions** CE-MRI at 7T is technically feasible and was well tolerated. The selective water excitation used in the dynamic sequence resulted in a good lesion to fat-and-fibroglandular-tissue contrast. Kinetic curves obtained at 7T and 3T both showed a similar rapid-initial enhancement and a similar pattern in the delayed phase for the most malignant curve, which is compatible with the histological type of tumor. The SNR measurements performed on both field strengths indicate that the SNR increases more at 7T following contrast injection, which may support the use of lower Gd dosage. High resolution imaging at 7T shows great detail of the mass and its spiculae. This initial experience suggest that CE-MRI of the breast is feasible at ultra-high field 7T. Having a robust clinical assessment of contrast enhancement with comparable or even better information content than at lower field strengths is an important requirement for the development of comprehensive high field MRI studies in breast cancer patients utilizing new ultra high field contrast mechanisms (e.g. ultra high resolution, Ca<sup>++</sup> detection and 31P metabolism).

**Reference** [1] Umutlu et al. Dynamic contrast-enhanced breast MRI at 7 Tesla utilizing a single-loop coil: a feasibility trial.

**Fig 2:** High resolution MRI (0.45 x 0.45 x 0.57mm) obtained at 7T (a) compared to the X-ray mammography (b, rotated Cranio-Caudal view, corresponding to the MRI orientation). Excellent lipid suppression was obtained using SPAIR which provided uniform suppression even in the presence of non uniform B1, thereby enabling detailed analysis