

Analysis of the Normalized Radial Length Reveals Differences in Morphology between Hormone Receptor Positive and Negative Breast Lesions Imaged with DCE-MRI

F. Liu^{1,2}, A. Kornecki³, O. Shmuilovich³, Y. Bureau^{1,2}, and N. Gelman^{1,2}

¹Imaging Division, Lawson Health Research Institute, London, Ontario, Canada, ²Department of Medical Biophysics, University of Western Ontario, London, Ontario, Canada, ³Department of Diagnostic Imaging, St. Joseph's Health Center, London, Ontario, Canada

Introduction: Several studies have investigated differences in quantitative morphological features between benign and malignant breast tumors, as assessed by dynamic contrast enhanced-MRI (DCE-MRI); however, very little information is available on the extent of such differences between certain subgroups of malignant tumors, such as hormone receptor positive and negative tumors. Such information should help to better understand and quantify the variability in morphology across malignant tumors. This abstract presents an investigation of quantitatively determined morphological features in hormone receptor positive and negative tumors. To assess the tumor surface irregularity, we have determined for each tumor measures of the intra-tumor variability of the radial length [1,2], which is the distance between a given point on the surface of the tumor and the tumor centroid. This measure is normalized by dividing by the intra-tumor mean of the radial length in order to remove the dependence on tumor volume, and is hence referred to as the normalized radial length (NRL).

Methods: DCE-MR images that had been acquired from 97 patients as part of clinical examinations between Jan. 1, 2005 and Jan. 1, 2007 were retrospectively included in this study following approval from our Institutional Ethics Review Board. The estrogen receptor (ER) and progesterone receptor (PR) status was available for 51 patients with 59 biopsy proven malignant tumors including those with hormone receptor status of ER+/PR+ ($N = 40$), ER-/PR- ($N = 10$), ER+/PR- ($N = 8$), ER-/PR+ ($N = 1$), including 54 invasive ductal carcinomas (92%), one ductal carcinoma in situ (2%), two invasive lobular carcinomas (3%) and two mucinous carcinomas (3%). **Image Acquisition:** The DCE-MRI had been performed on a 1.5 T Siemens MRI system with a two-element breast coil (Siemens Avanto, Siemens, Erlangen, Germany). The 3D spoiled gradient echo sequence known as volume interpolated breath hold imaging (VIBE) was used with the following parameters: TR/TE = 4.5 ms/1.2 ms, flip angle = 20°, fat saturation with SPAIR. The image matrix size was 448 × 318 × 100, interpolated to 512 × 512 × 160 with a field of view ranging from 300 mm × 300 mm × 176 mm to 350 mm × 350 mm × 176 mm. Contrast agent administration involved manual injection of a 20 ml dose of gadopentetate dimeglumine (Gd-DTPA) (Magnevist, Bayer HealthCare Pharmaceuticals, USA) over 15 s to 20 s. The DCE acquisition consisted of 1 pre-contrast image and 7 post-contrast images with a temporal resolution of 1 min, with the middle of first post-contrast image occurring 1 min after the start of Gd-DTPA administration. **Tumor Segmentation:** A 3D rectangular box enclosing the tumor was positioned by a radiologist (O.S.) on the first post-contrast image. Voxels inside the box were classified into two clusters by K-means clustering applied to the images obtained by subtracting the pre-contrast image from each post-contrast image. The cluster with the higher signal enhancement on the first post-contrast image averaged across all voxels was considered as the tumor. **Morphological Features:** The Radial Length was determined for each surface voxel of the tumor. This was defined as the length of the shortest intra-tumor pathway from this surface voxel to the centroid of the tumor. The radial lengths were normalized by dividing by the mean of all radial lengths of the tumor, with the resulting measure referred to as the normalized radial length (NRL). Three features characterizing the NRL distribution of each tumor were extracted, including the standard deviation (NRLSD), skewness (NRLskewness) and kurtosis (NRLkurtosis). Tumor volumes were also determined. **Statistical Analysis:** The student's *t*-test was applied to compare these morphological features and tumor volume between ER+/PR+ tumors, ER-/PR- tumors and ER+/PR- tumors. A *p* value of less than 0.05 / (3 comparisons) = 0.0167 (i.e., Bonferroni correction for three comparisons) indicated significance. The statistical analysis did not include the ER-/PR+ group which contained only one tumor.

Results: A comparison between ER+/PR+ and ER-/PR- breast tumors in terms of the morphological features considered is provided in Table 1. Significant differences were obtained for NRLSD ($p < 0.0001$), but not for NRLskewness, NRLkurtosis or tumor volume. No significant differences were found between ER+/PR- and either ER-/PR- or ER+/PR+. A comparison of NRLSD values for all four hormone receptor groups is illustrated in Figure 1.

Discussion: The larger NRLSD in ER-/PR- tumors compared to ER+/PR+ tumors indicates a broader NRL distribution, which may be due to larger variations on the tumor surface (i.e., "rougher surface"). The trend toward larger positive NRLskewness of ER-/PR- compared to ER+/PR+ tumors (see Table 1, $p = 0.04$, not significant if considering Bonferroni correction) may indicate a longer tail in the positive direction of the NRL distribution, which may be due to long tumor extensions from the tumor center. The similar tumor volumes in the ER+/PR+ and ER-/PR- tumors studied here suggests that the comparison of NRL features is not likely biased by differences in volumes; however, this would need to be confirmed by a multivariate analysis. These tumor volume results differ from those of previous studies which have more typically found hormone receptor negative tumors to be larger than hormone receptor positive tumors within the tumor data sets studied [3,4].

Conclusion: Our results indicate differences in tumor morphology between hormone receptor positive and negative tumors. These differences, based on the intra-tumor variation of the normalized radial length suggest that ER-/PR- tumors may have larger surface irregularities than ER+/PR+ tumors.

References:

1. Kilday, J., et al., IEEE Tran Med Imaging 1993; 12: 664-669
2. Nie, K., et al., Acad Radiol 2008; 15: 1513-1525
3. Baltzer P.A.T., et al., Eur Radiol 2010; 20: 1563-1571
4. Chen J.H., et al., J Magn Reson Imaging 2008; 27: 825-833

	Mean ± SD		
Morphological features	ER+/PR+ (N = 40)	ER-/PR- (N = 10)	<i>p</i> value
Volume (cm ³)	13.8 ± 26.0	13.5 ± 11.7	0.97
NRLSD	0.28 ± 0.10	0.43 ± 0.08	< 0.0001
NRLskewness	0.67 ± 0.58	1.11 ± 0.59	0.04
NRLkurtosis	4.18 ± 1.57	4.71 ± 2.30	0.39

Table 1. Comparison of morphological features between ER+/PR+ and ER-/PR- breast tumors

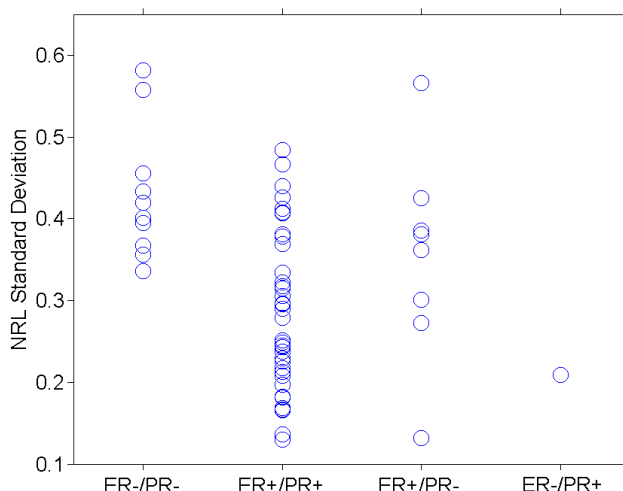


Figure 1. The standard deviation of normalized radial length distribution (NRLSD) comparison for all four hormone receptor groups