

Ultrafast dynamic imaging of the breast at diagnostic spatial resolution using TWIST

R. M. Mann¹, R. D. Mus¹, C. Geppert², J. O. Barentsz¹, and H. Huisman¹

¹Radiology, Radboud University Nijmegen Medical Centre, Nijmegen, Gld, Netherlands, ²MR Oncology, Siemens Healthcare, Erlangen, Germany

Purpose:

To evaluate the use of a TWIST (time-resolved angiography with stochastic trajectories) sequence [1] to overcome the inherent choice between high spatial resolution and high temporal resolution in breast MRI.

Introduction:

The current standard of breast MRI demands a spatial resolution of at least 1*1*2.5 mm in breast MRI [2]. The maximal slice thickness is chosen to ascertain detection of all lesions of 5 mm and larger, whereas the inplane resolution of 1*1 mm is mandatory for adequate morphological evaluation. At least three time points (prior to contrast administration, at the peak of enhancement and in the late phase of enhancement) are recorded for evaluation of the enhancement versus time curve. This combined analysis of morphological and dynamic features is thought to yield the highest accuracy in differentiating benign from malignant breast lesions.

Nevertheless recent studies have shown that pharmacokinetic modeling of contrast enhancement alone using ultrafast dynamic sequences (<10s) results in lesion classification with an accuracy comparable to this combined approach [3]. Moreover adding this data to the combined approach increases the overall accuracy [3]. So far, however, these ultrafast dynamic sequences do not produce a spatial resolution that is sufficient for morphological analysis or lesion detection. Therefore such sequences can only be used in a combined scanning protocol, interleaving ultrafast dynamic sequences in a series of slower sequences with a high spatial resolution. We aimed to test whether breast MRI using an ultrafast TWIST sequence would allow both morphological analysis and pharmacokinetic modeling from the same dataset.

Methods:

9 patients who underwent breast MRI at our institution for varying indications (high risk screening = 6, preoperative staging = 1, BI-RADS 0 after mammography and ultrasound = 1, MR-guided marking of a tumor prior to neoadjuvant chemotherapy = 1), at 3T (Siemens Magnetom Trio, Erlangen Germany) using a 4 channel bilateral breast coil (Invivo Orlando, USA) were scanned with a slightly modified protocol. A TWIST sequence (transversal orientation, FOV 360 mm, slice thickness 2.5 mm, 60 slices, TR 4.5 ms, TE 2.3 ms, GRAPPA 2) in which k-space is divided in a central zone and a peripheral zone that were both radially sampled was employed prior to, during and in the first two minutes after contrast administration (17 timepoints), preceded and followed by high resolution 3D turboflash acquisitions with a spatial resolution of 0.9*0.9*1 mm that lasted 107 seconds each. In the TWIST acquisitions the central zone, that consisted of 15% of k-space, was sampled fully for each timepoint. The peripheral zone was first populated prior to contrast administration using a baseline scan lasting 26.6 seconds and thereafter sampled with reduced density at complementary trajectories, which were shared between successive timepoints. Consequently, at a spatial resolution of 1.0 * 0.9 * 2.5 mm, a temporal resolution of 6.89 seconds was achieved.

Results:

The SNR of the TWIST sequences was approximately 84% of the SNR of the high resolution acquisitions, which did not affect visual interpretation. Morphological analysis in the transversal plane was as good on the TWIST sequences as on the high resolution acquisitions. In all patients, the MRI could be interpreted on the basis of the TWIST sequences alone, using color maps of pharmacokinetic parameters and morphological characteristics (Fig 1). Moreover the creation of serial subtraction images and maximum intensity projections allowed good separation of lesions from normal enhancing glandular breast tissue (Fig 2). Presence of wash-out could not be evaluated because we did not perform TWIST acquisitions in the late phase of enhancement.

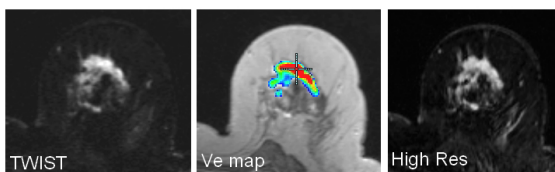

Fig 1. Morphological and pharmacokinetic data derived from the TWIST sequence allow lesion characterization. The morphological data is almost identical to the data derived from the High Res acquisition.

Conclusion:

Breast MRI using TWIST allows simultaneous high spatial and high temporal resolution imaging of both breasts and therefore reduces the need to choose between competing techniques. Moreover it allows interpretable breast MRI in a timeframe of only 2.30 minutes, which opens new perspectives for screening with MR.

References:

1. Laub et al. Proc ISMRM 2007, 3058
2. Mann et al. Eur Radiol. 2008 Jul;18(7):1307-18
3. Veltman et al. Eur Radiol. 2008 Jun;18(6):1123-33

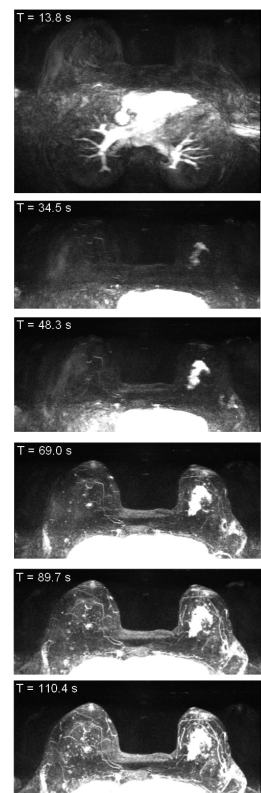


Fig 2. Serial MIPs allow separation of the large ILC in the left breast from enhancing glandular tissue as seen on the right side. Note that there is also a small early enhancing mass on the right side.